

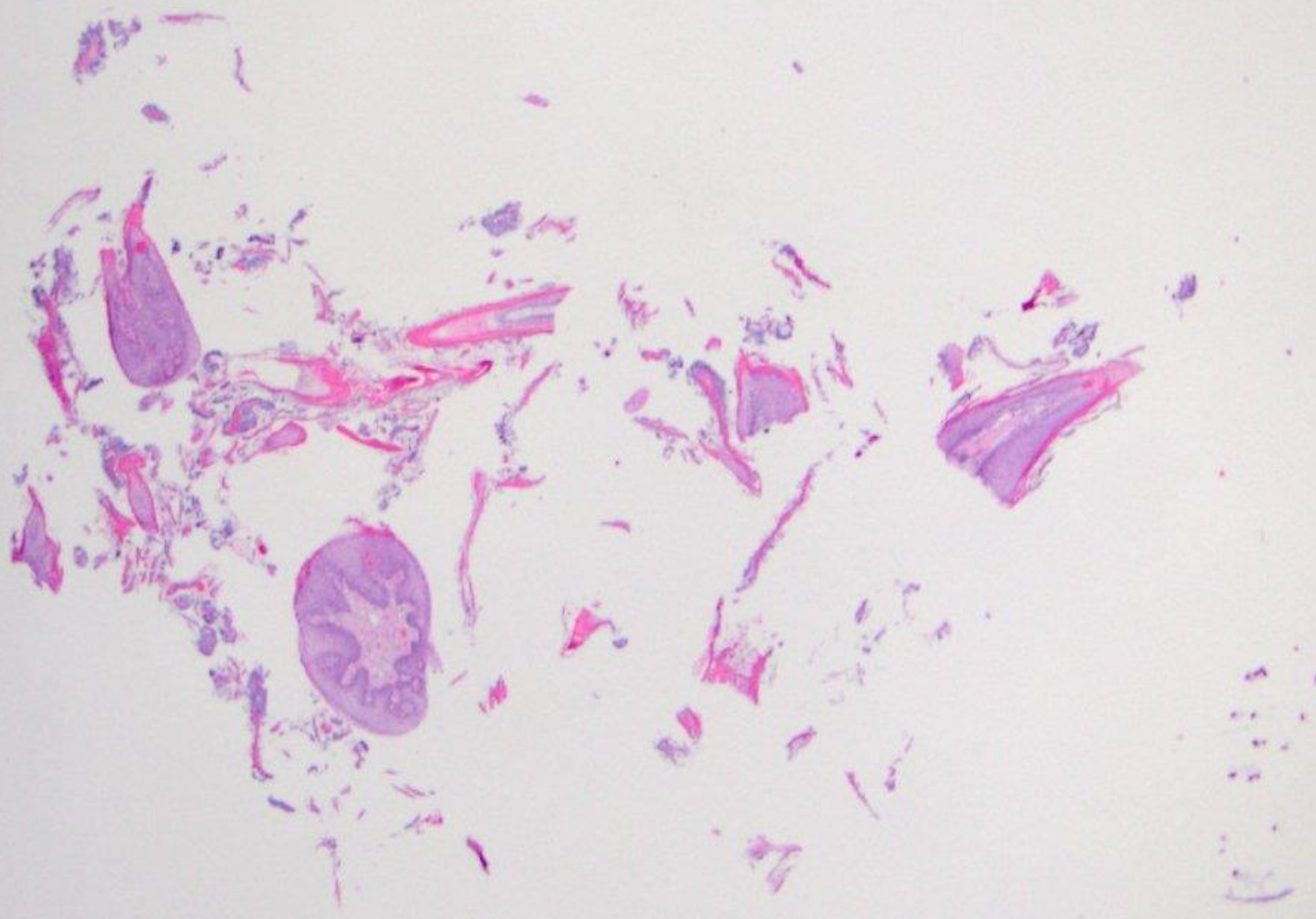
Oral Histopathology

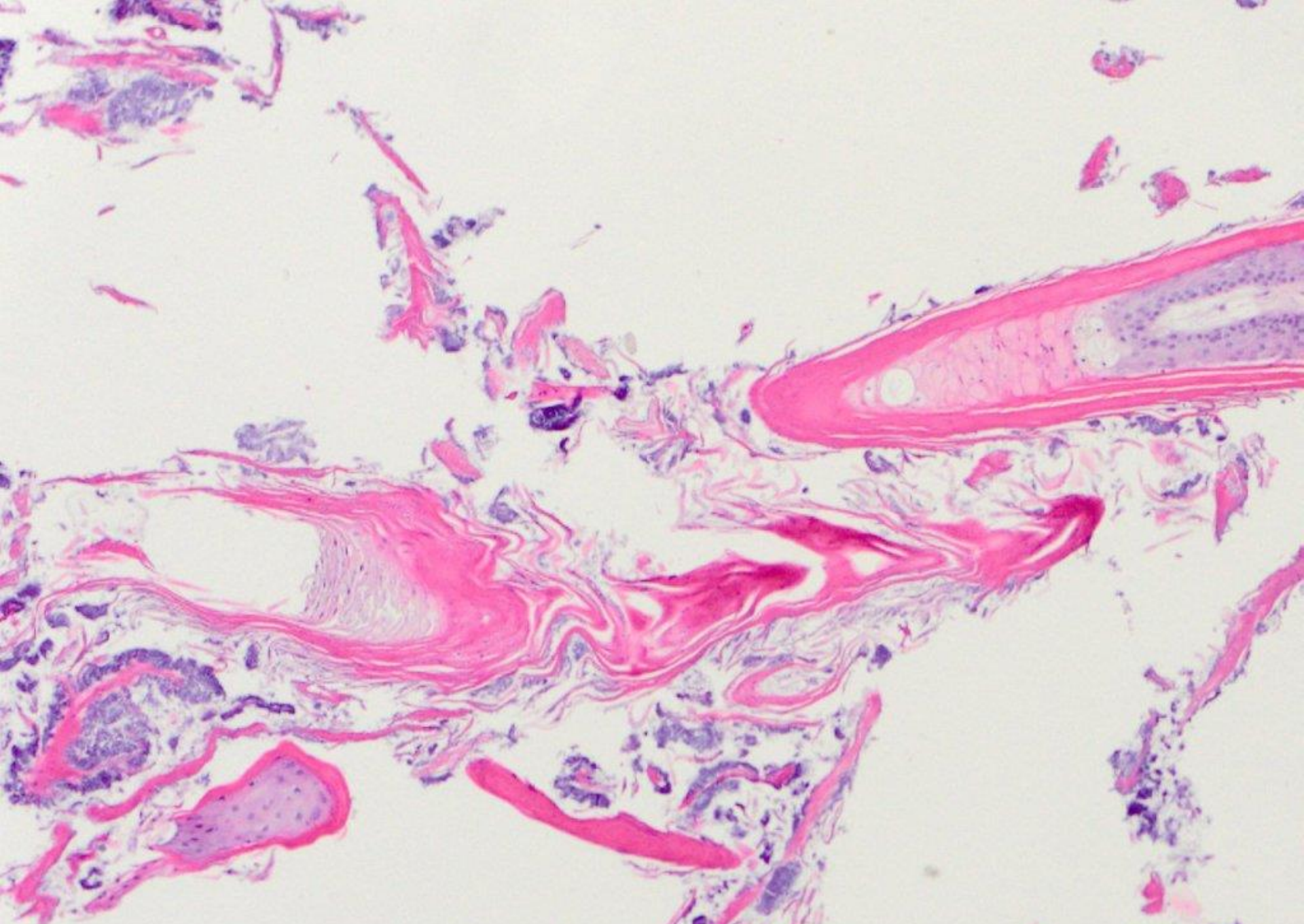
Series 32

DAVID E. KLINGMAN, DMD

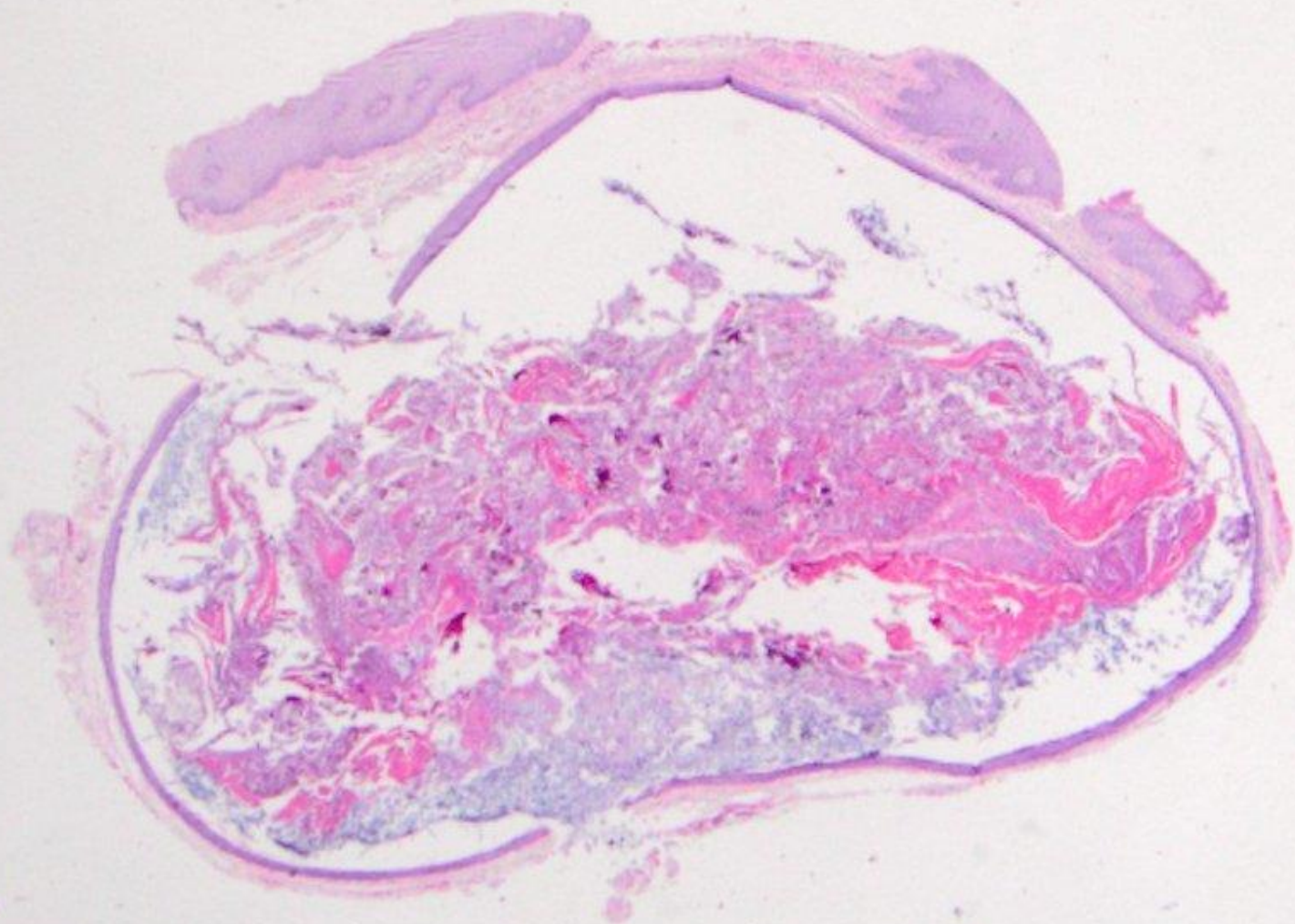
Diplomate, American Board of Oral and Maxillofacial Pathology

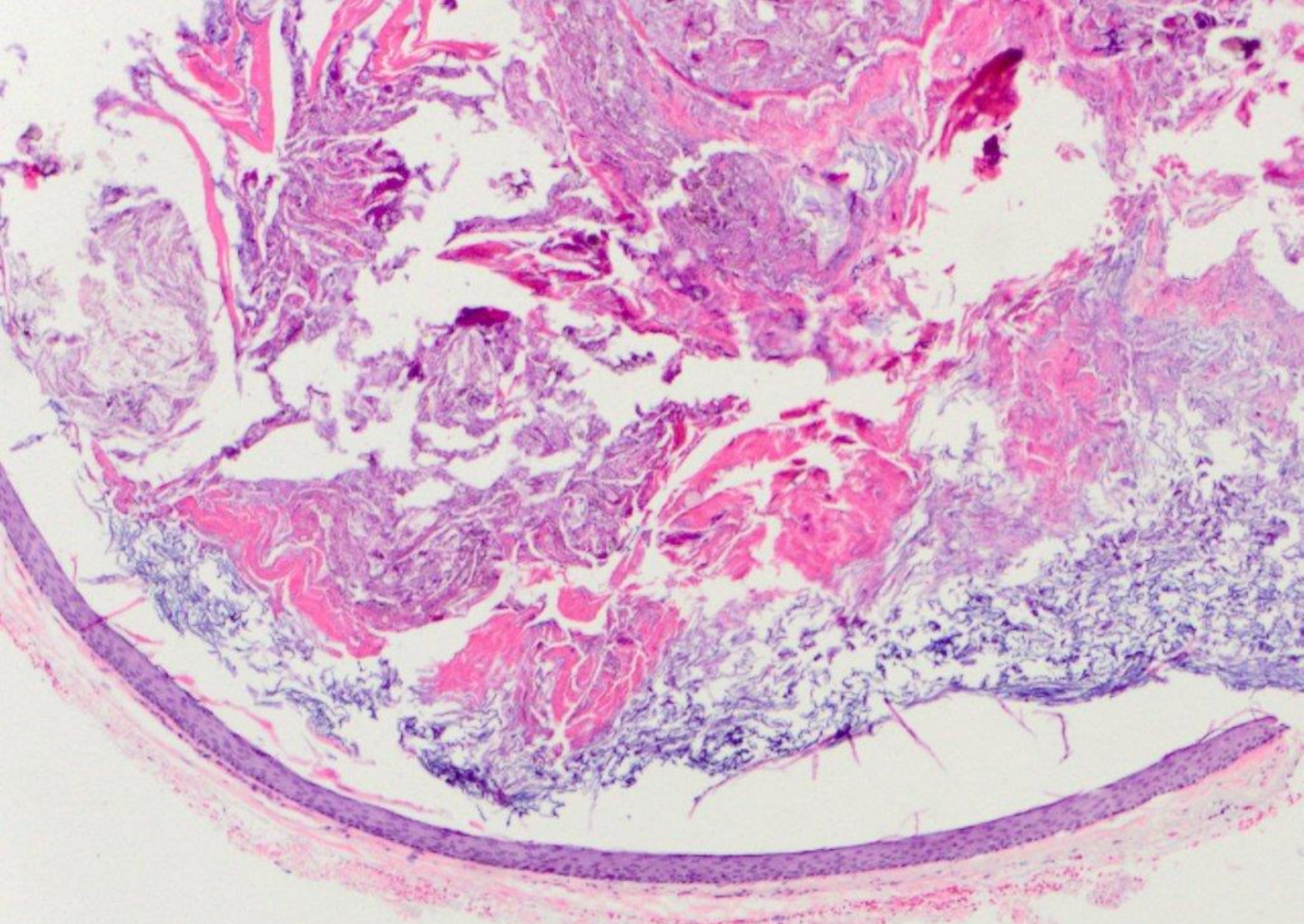
Diplomate, American Board of General Dentistry



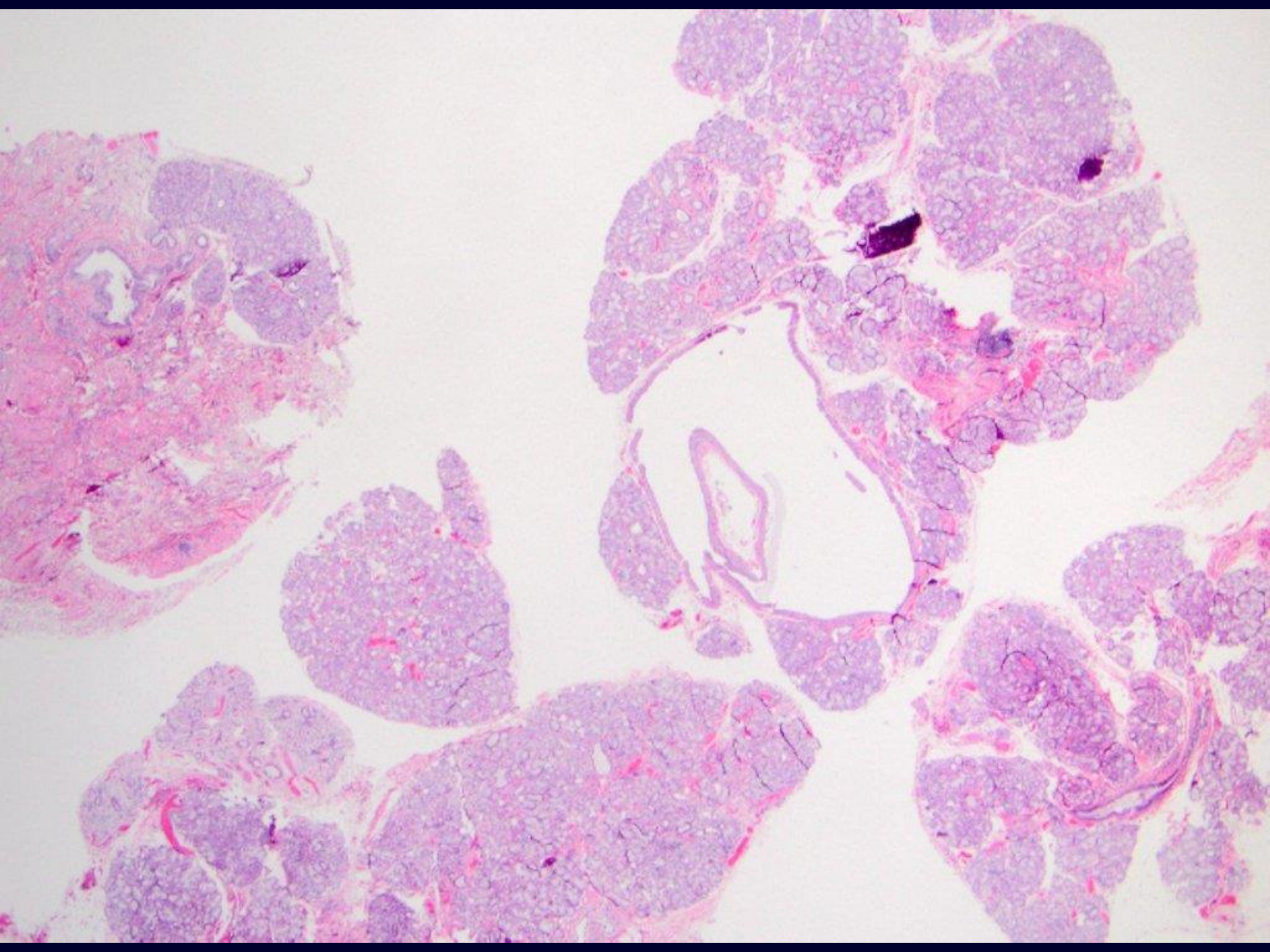


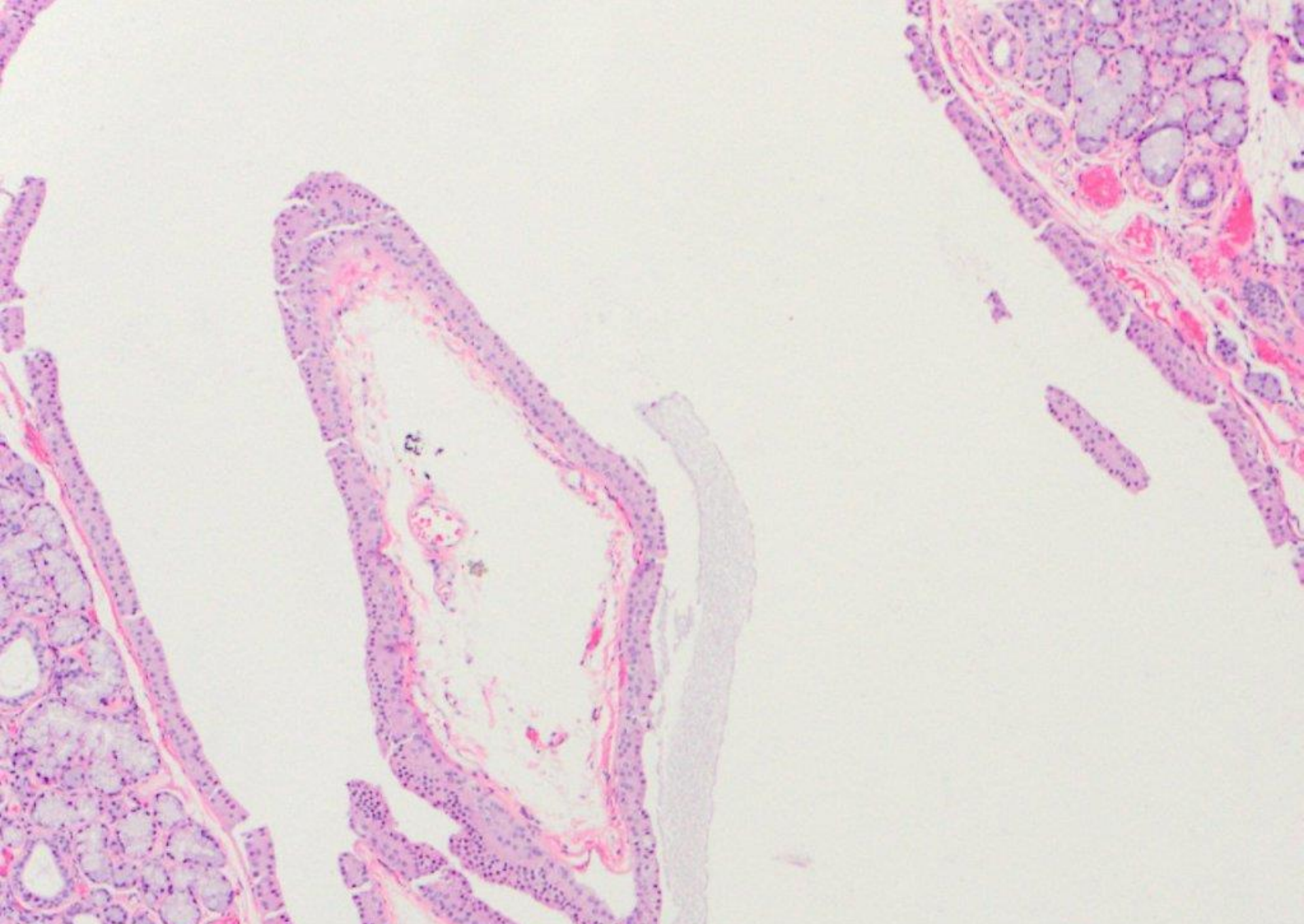
hairy tongue



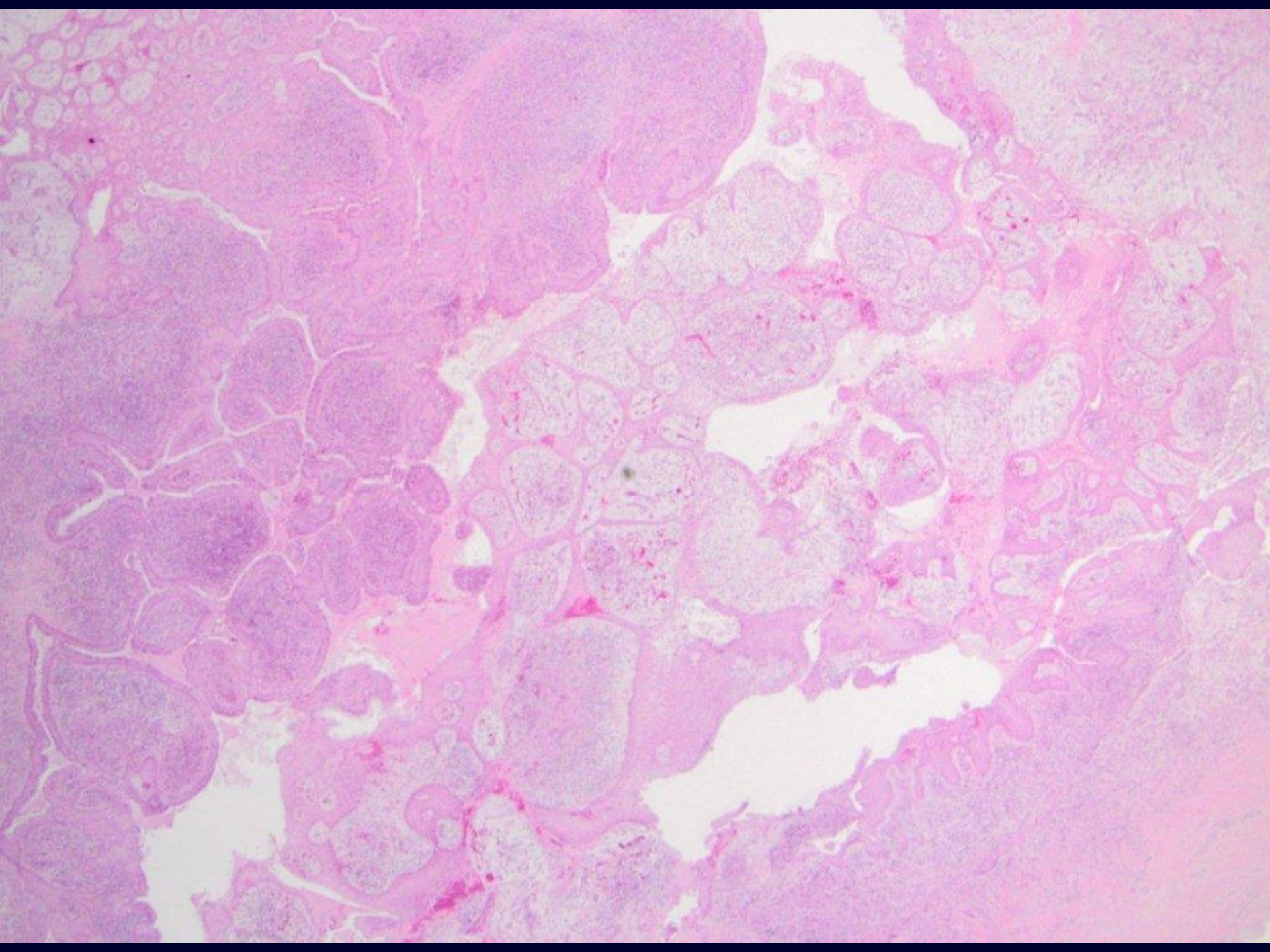


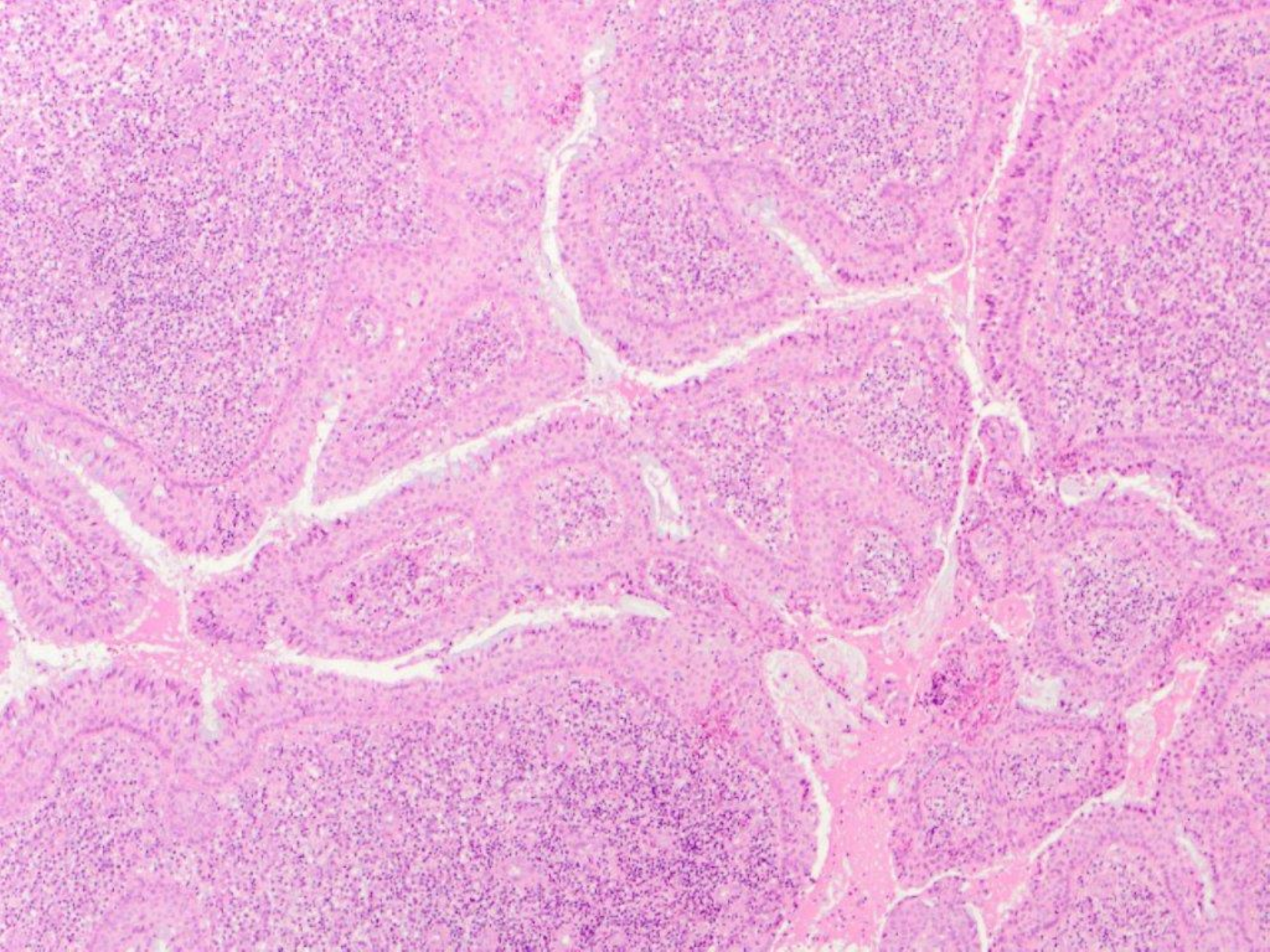
epidermoid cyst

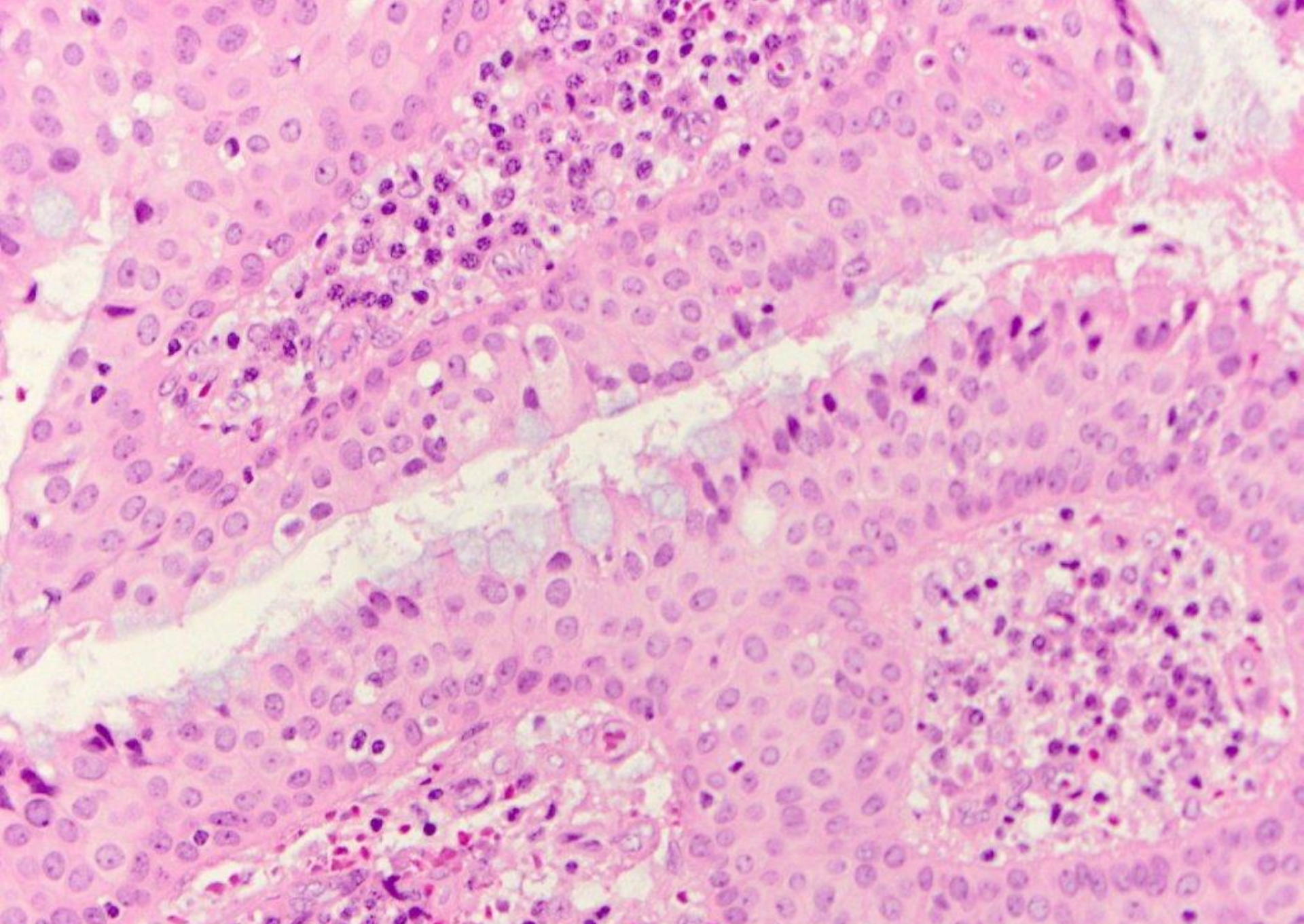




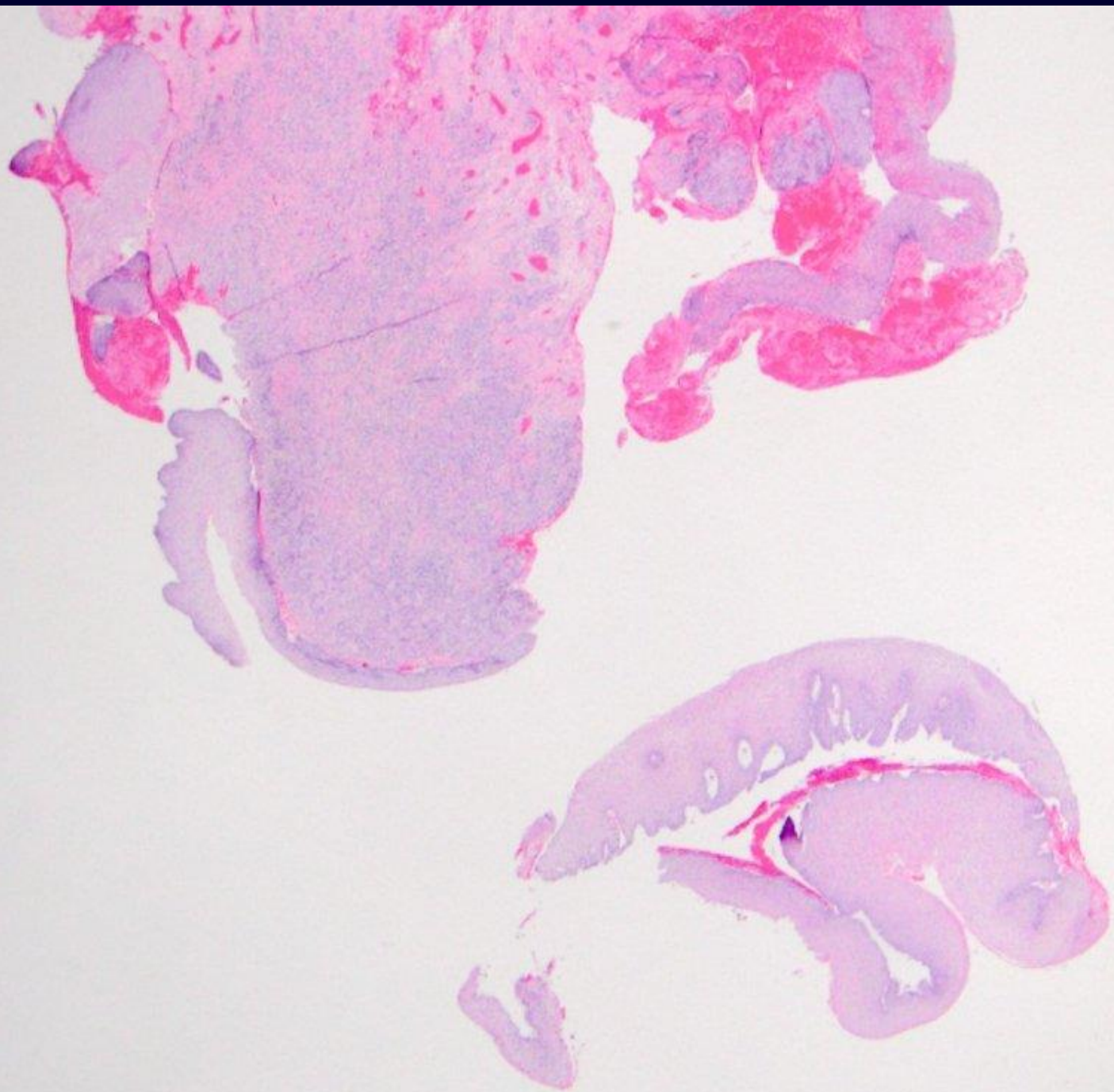
salivary duct cyst

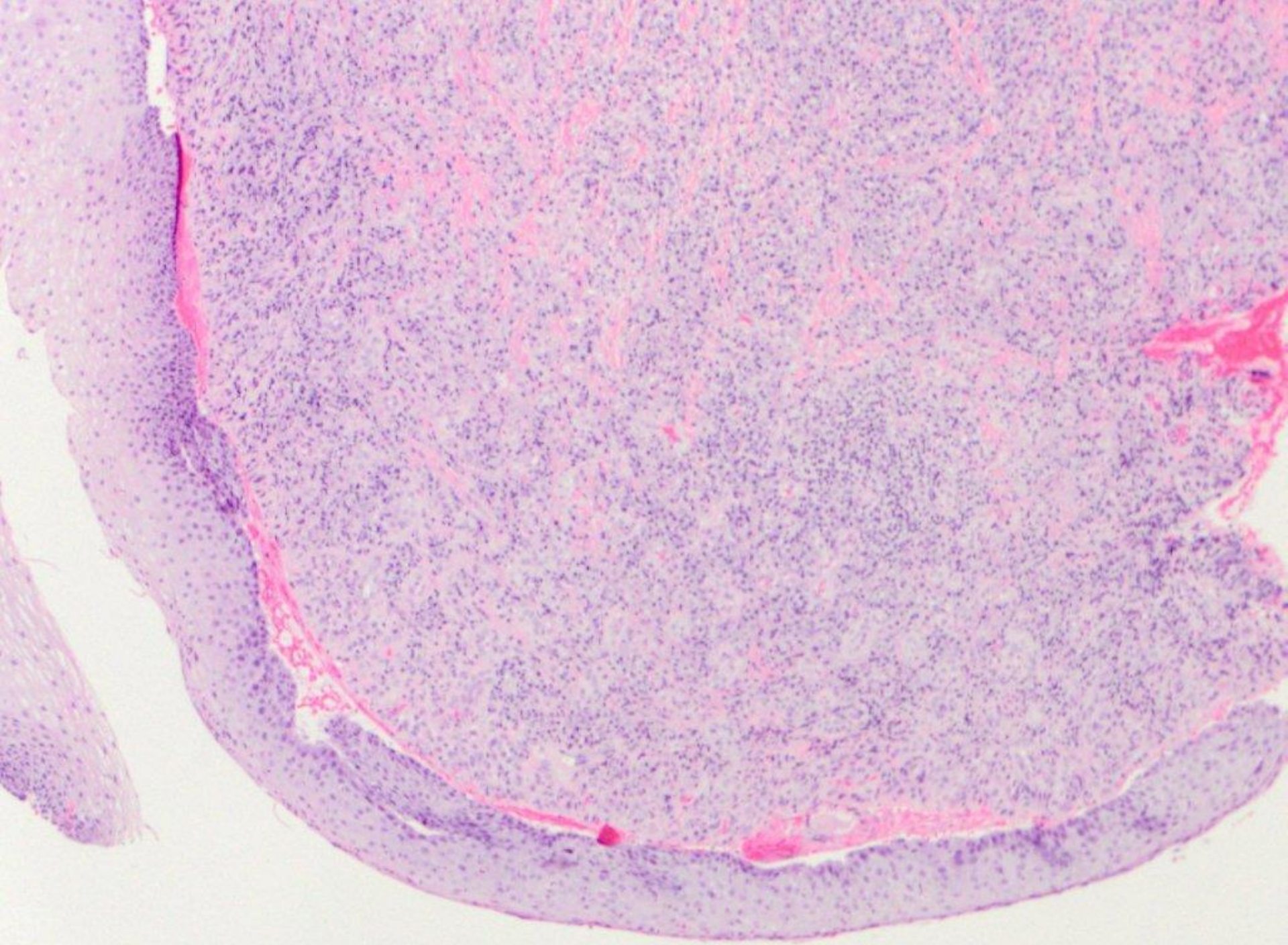


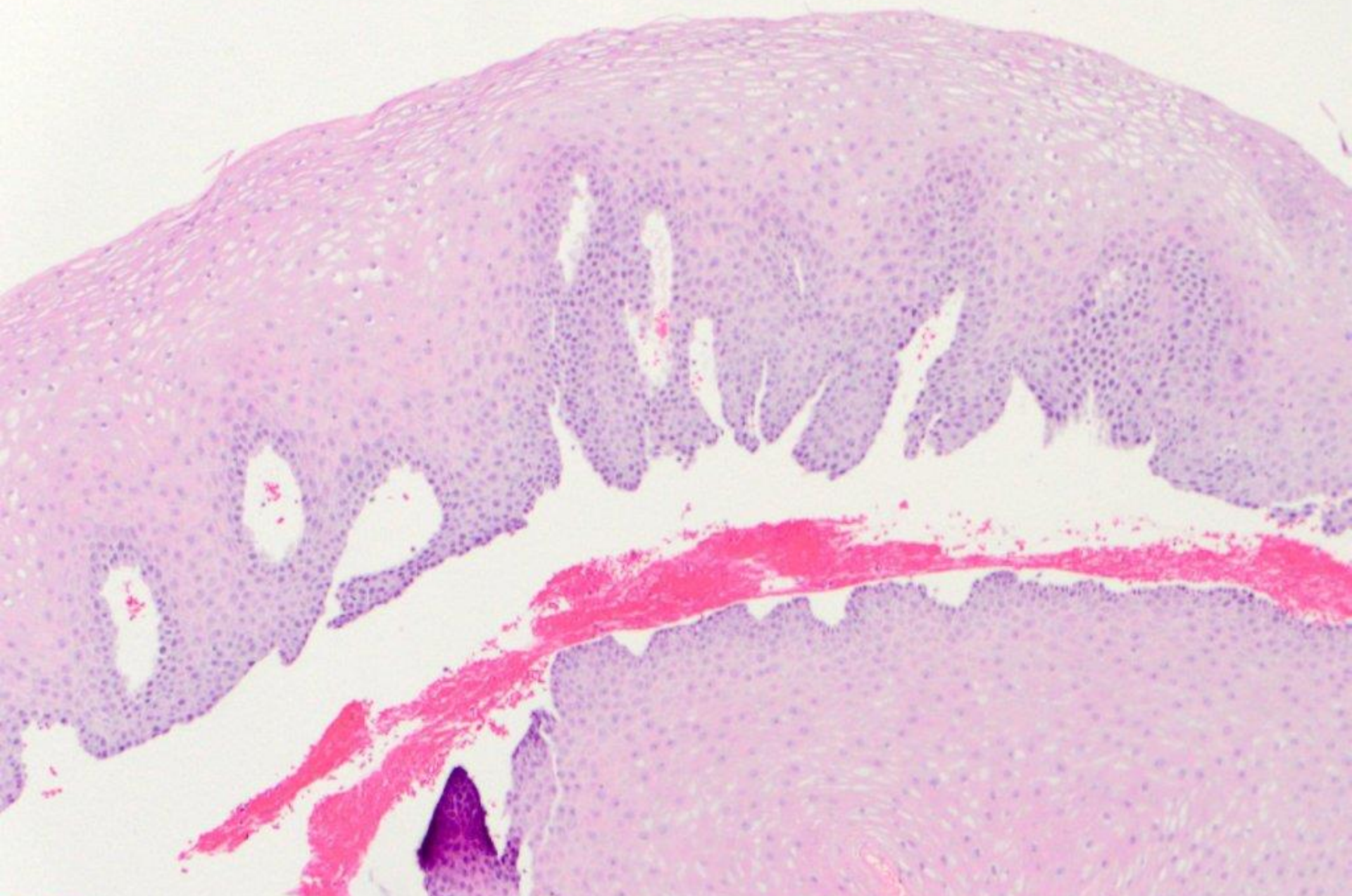




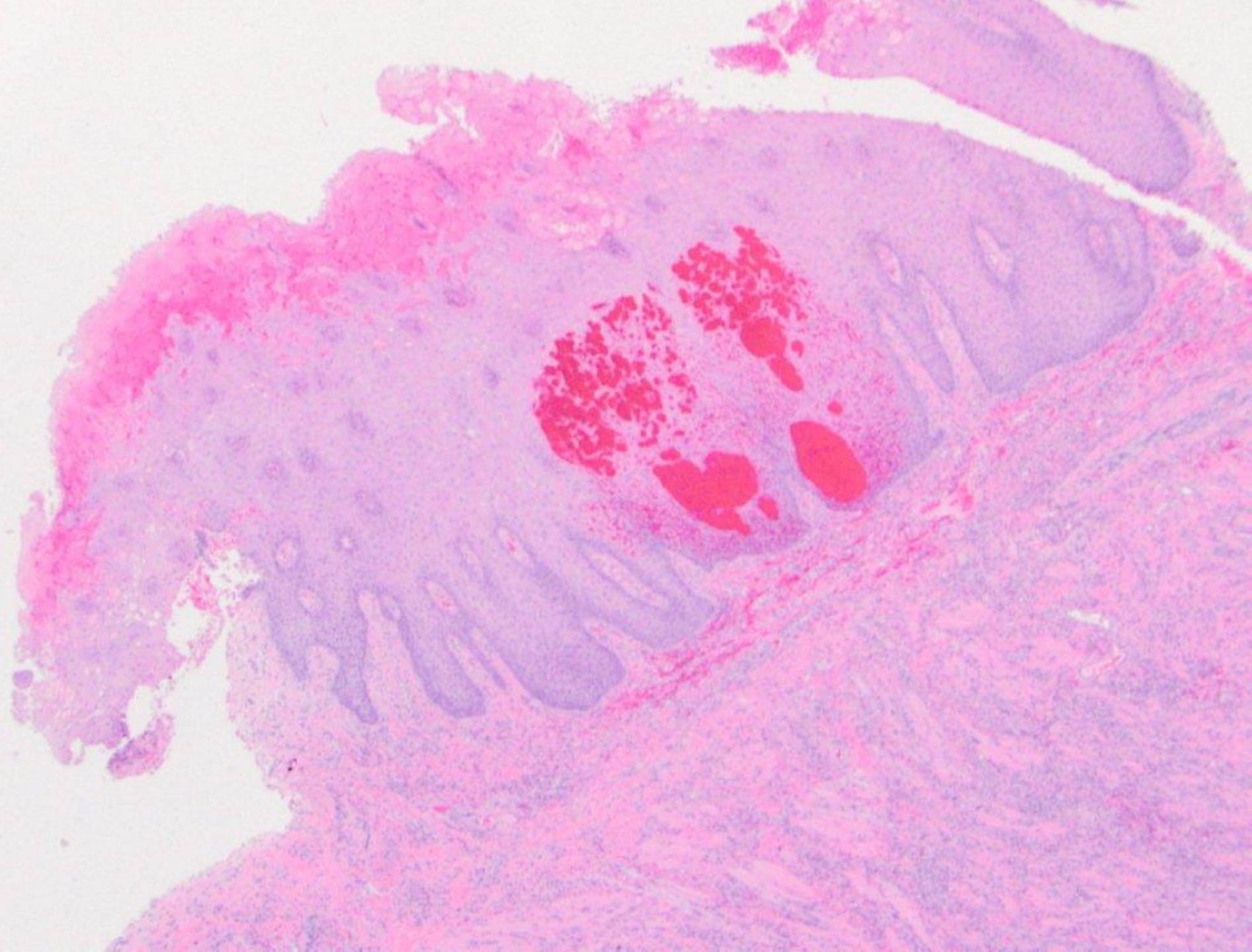
nasopalatine duct cyst, inflamed

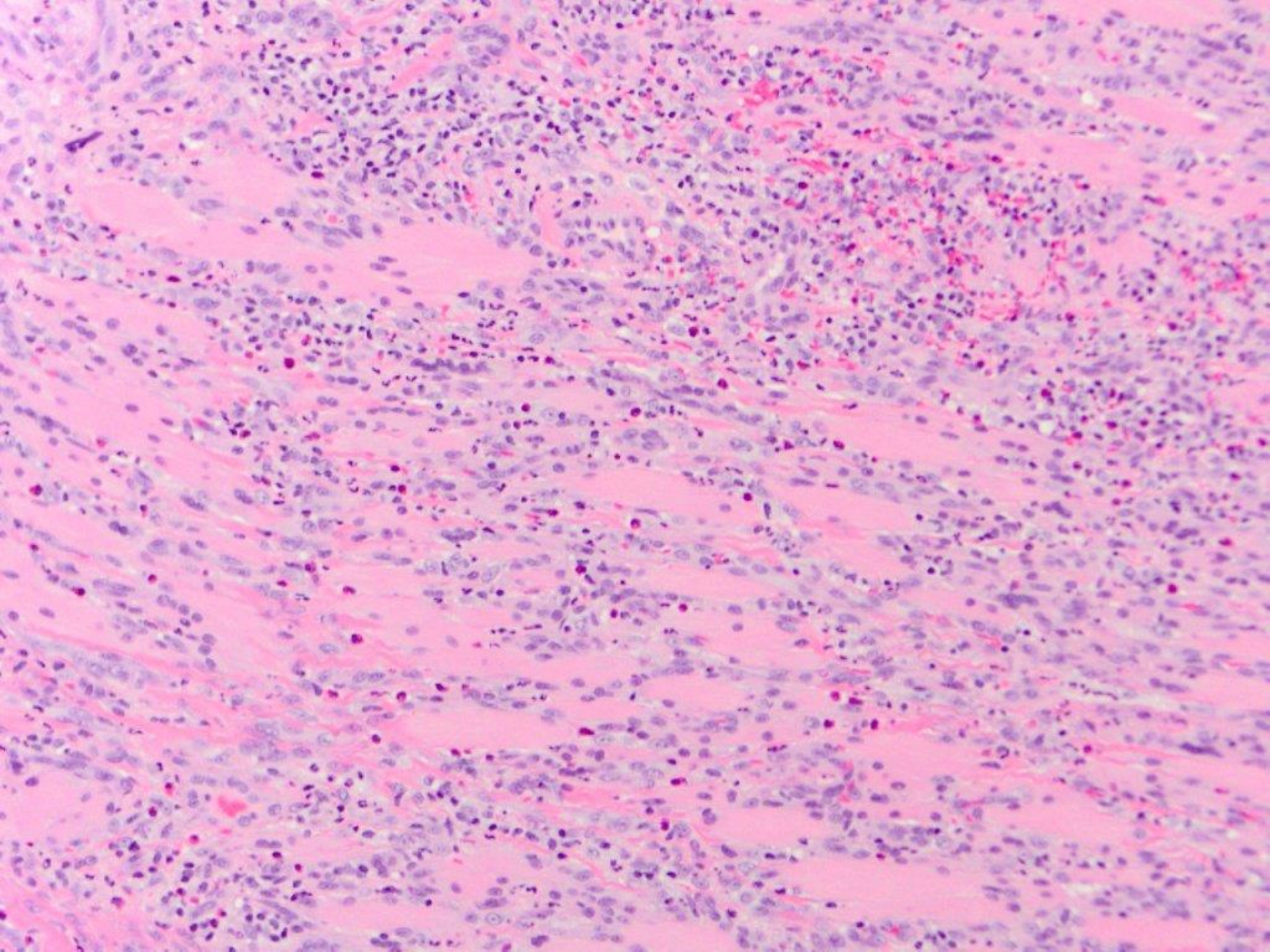


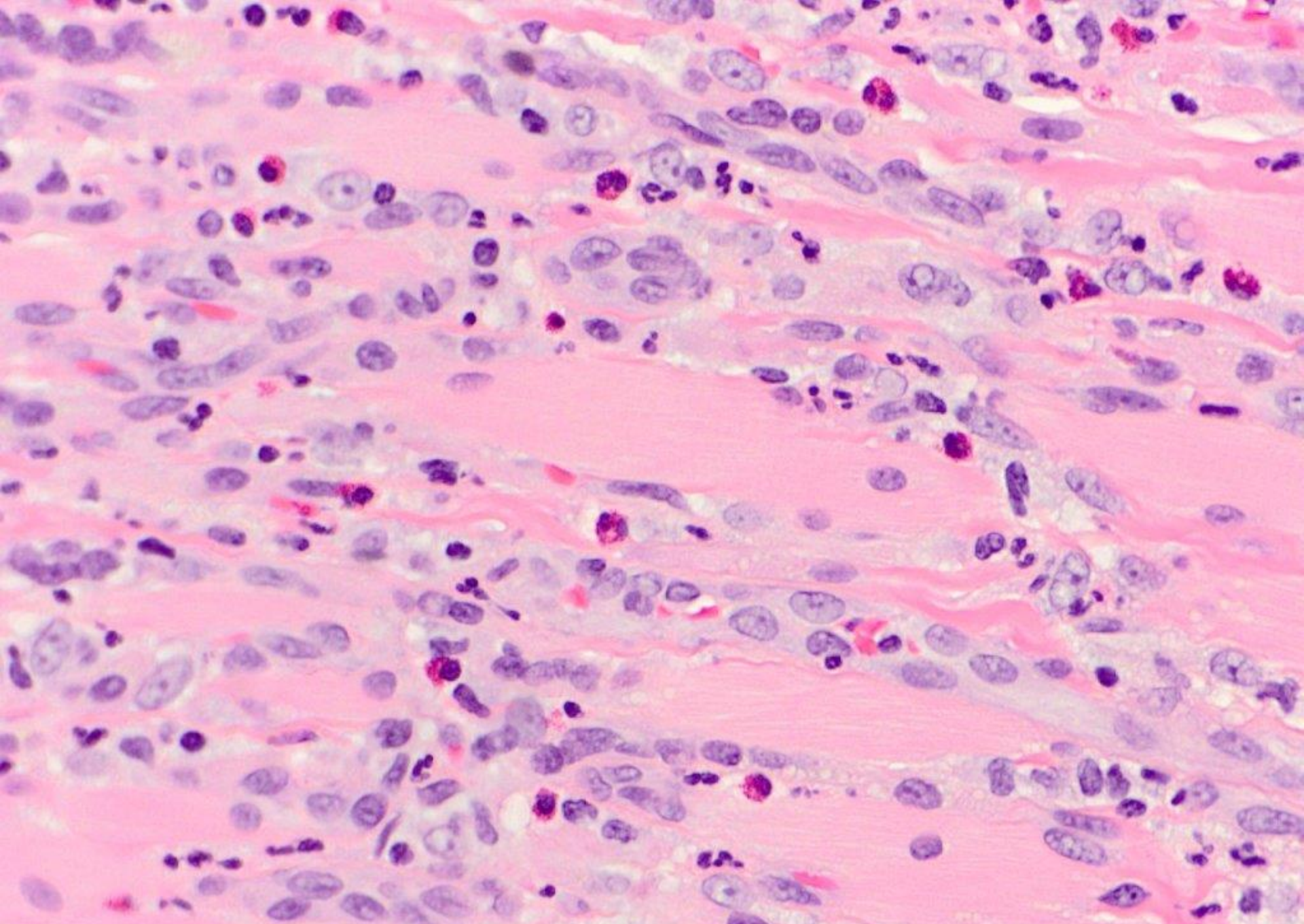




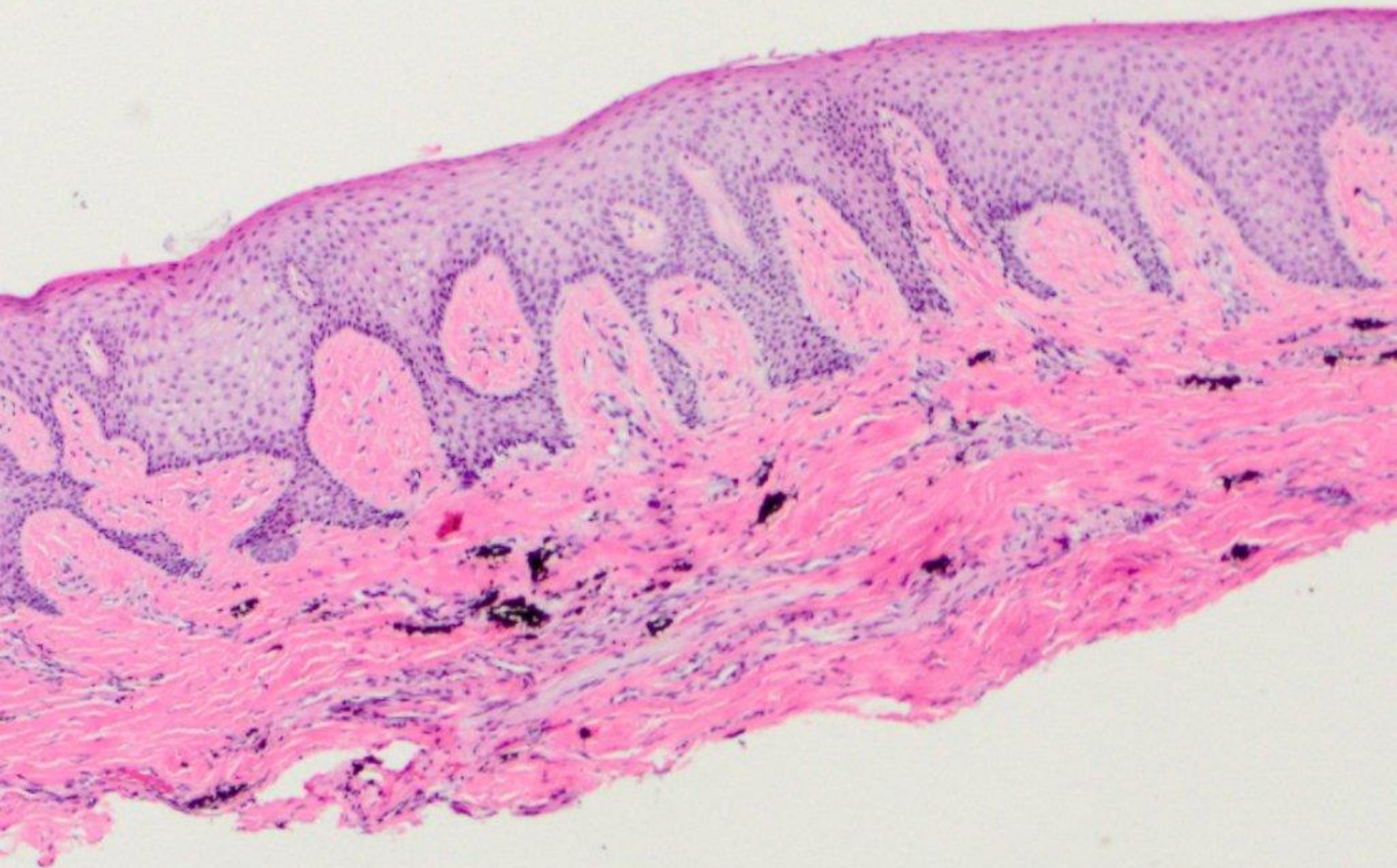
pemphigoid



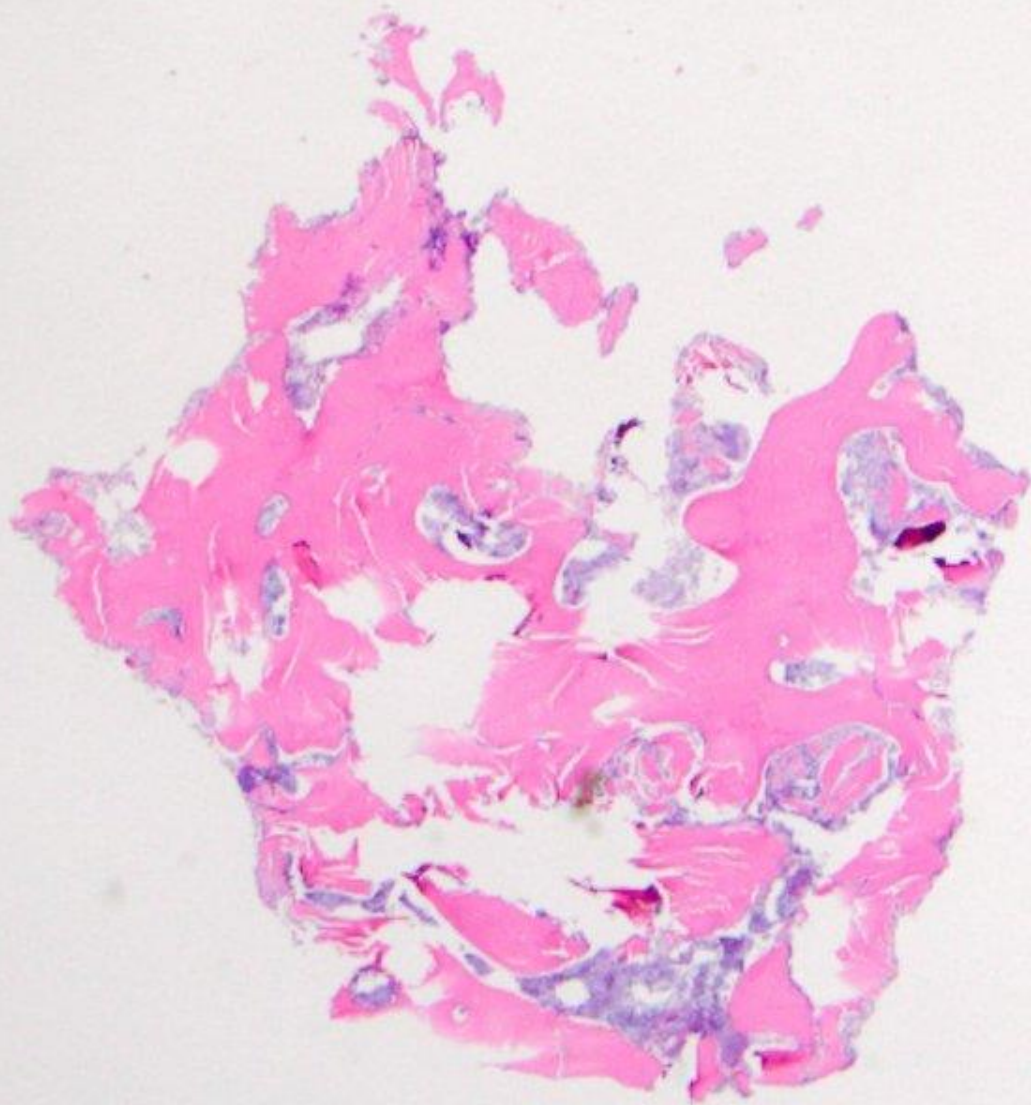


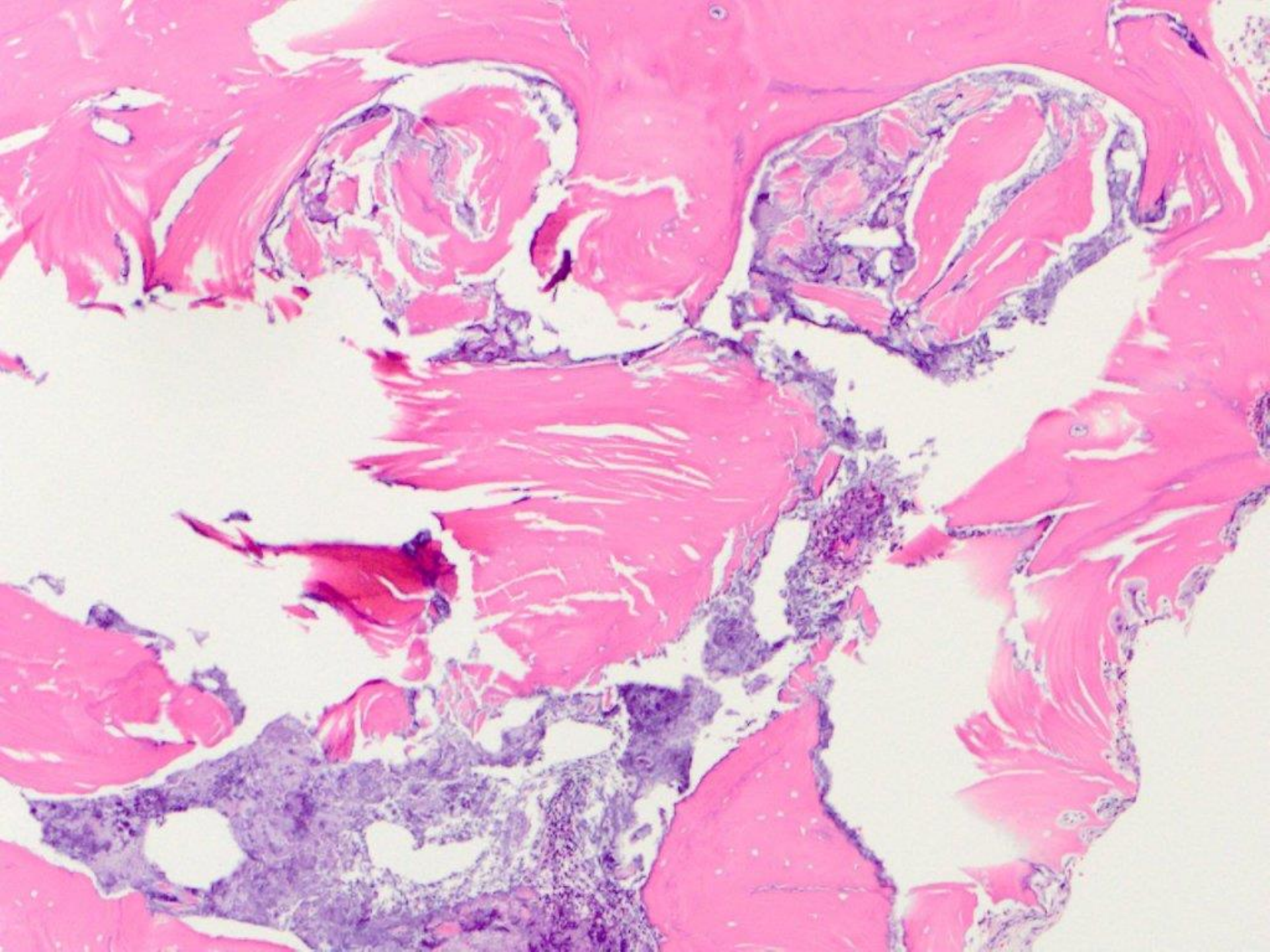


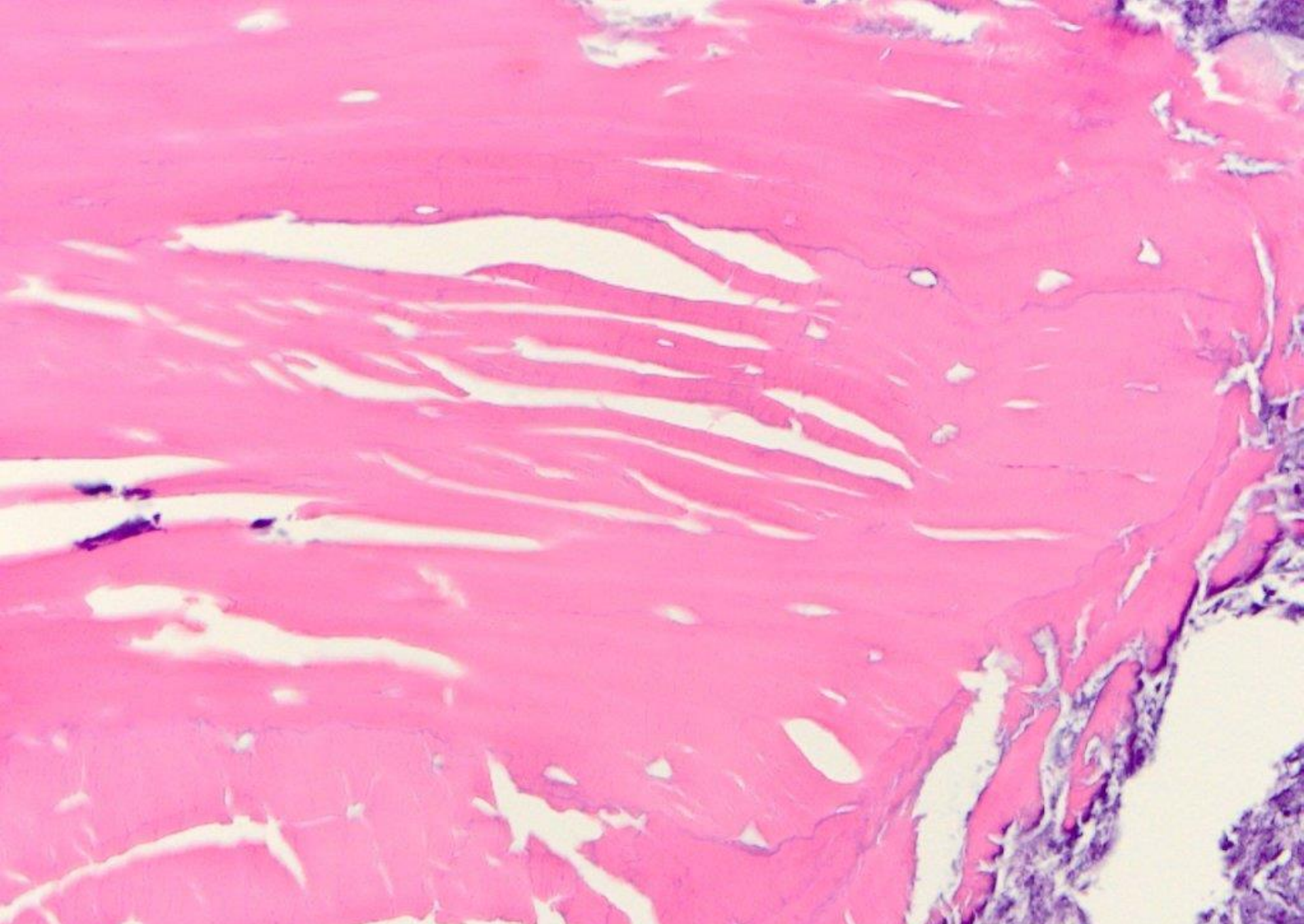
nonspecific (traumatic) ulcer with stromal eosinophilia (“TUGSE”)



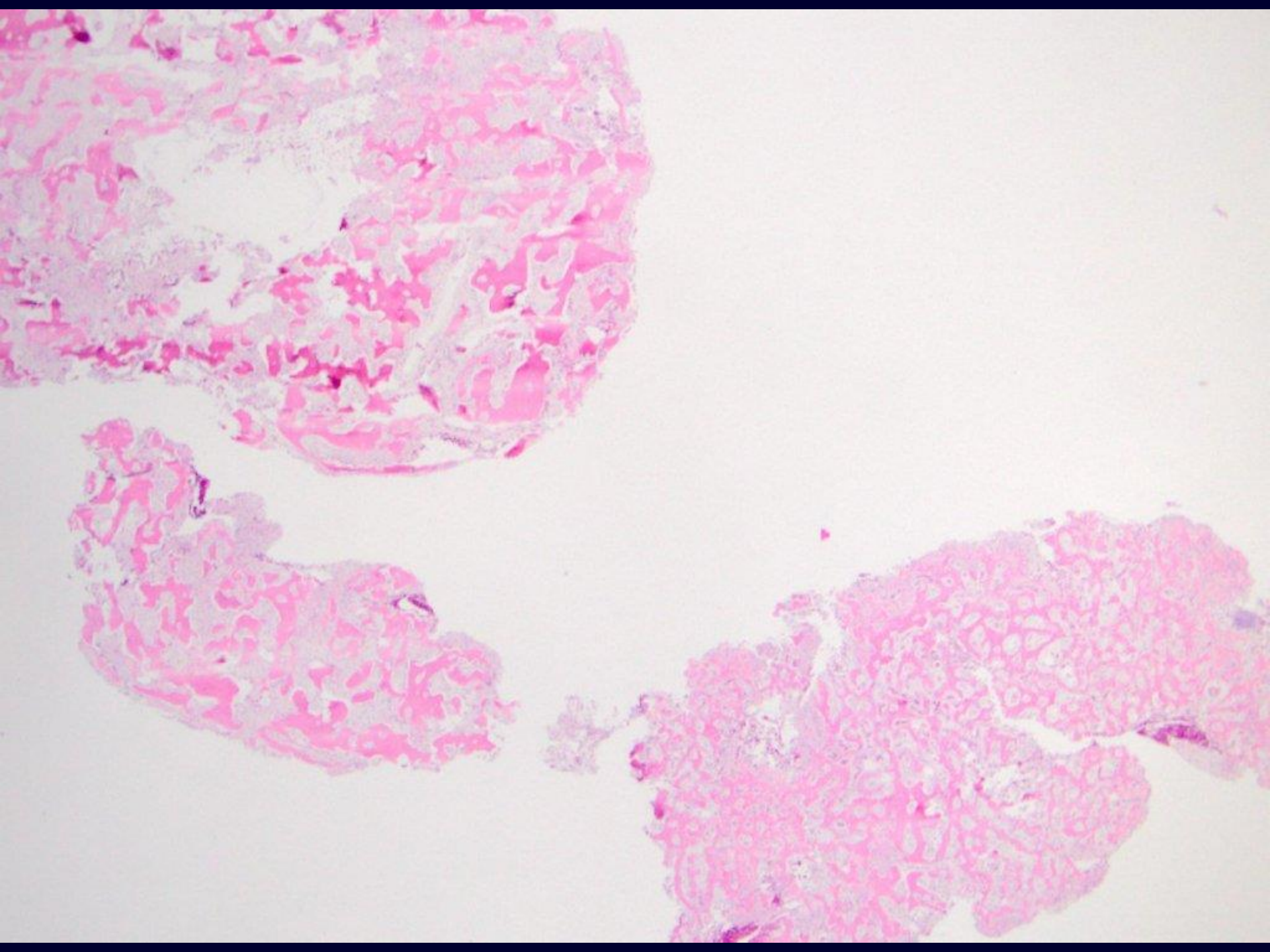
amalgam tattoo

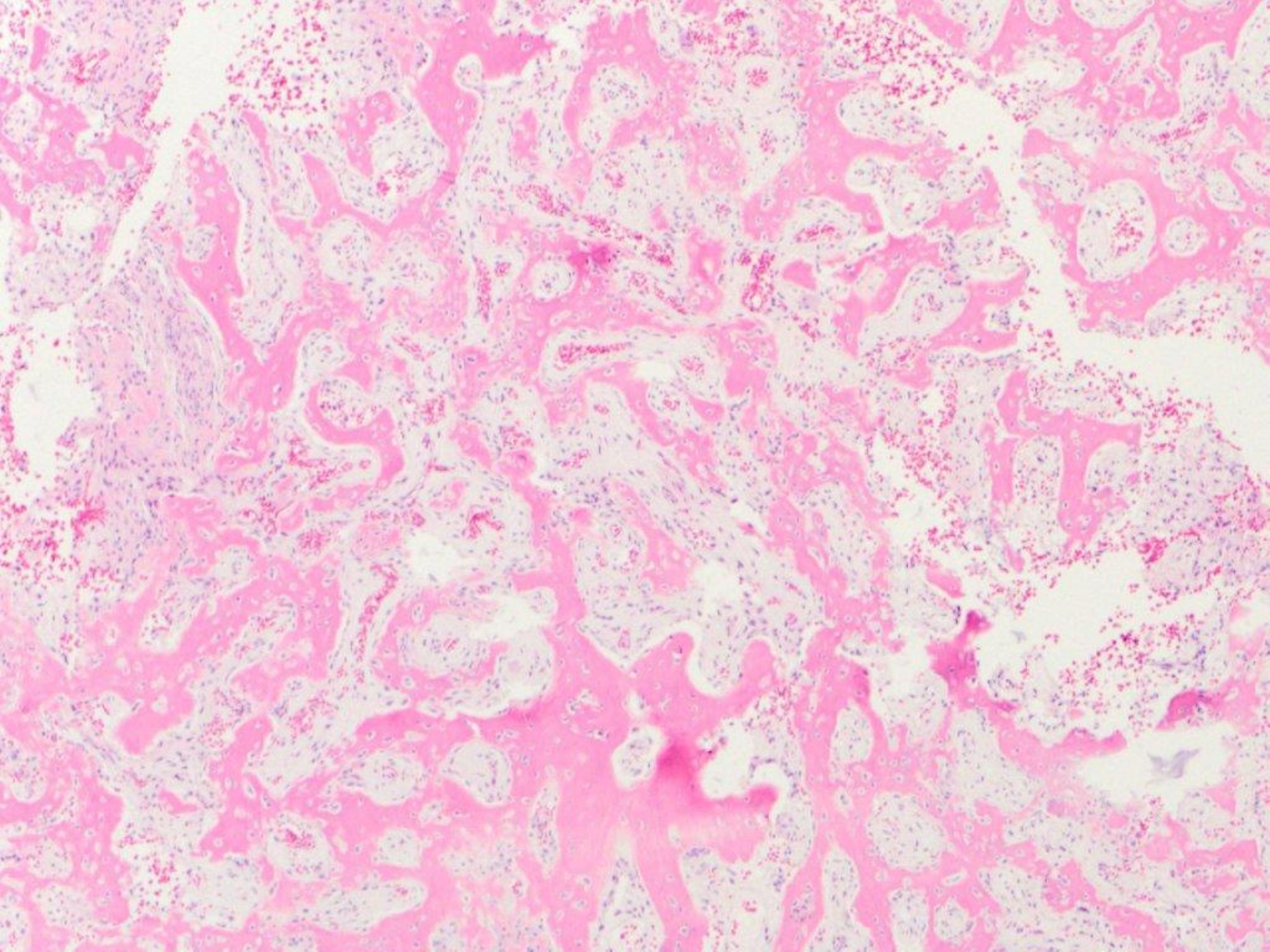


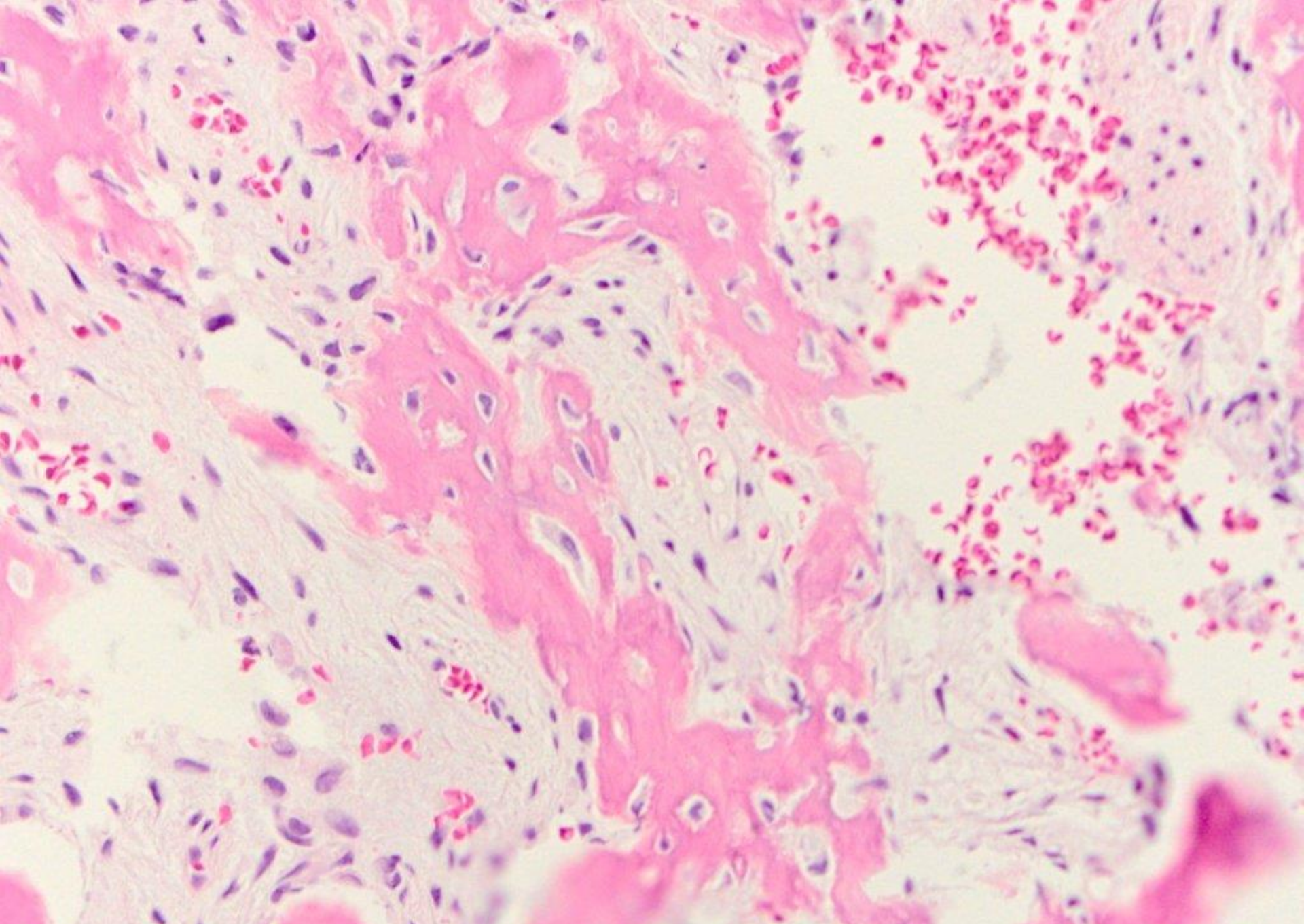




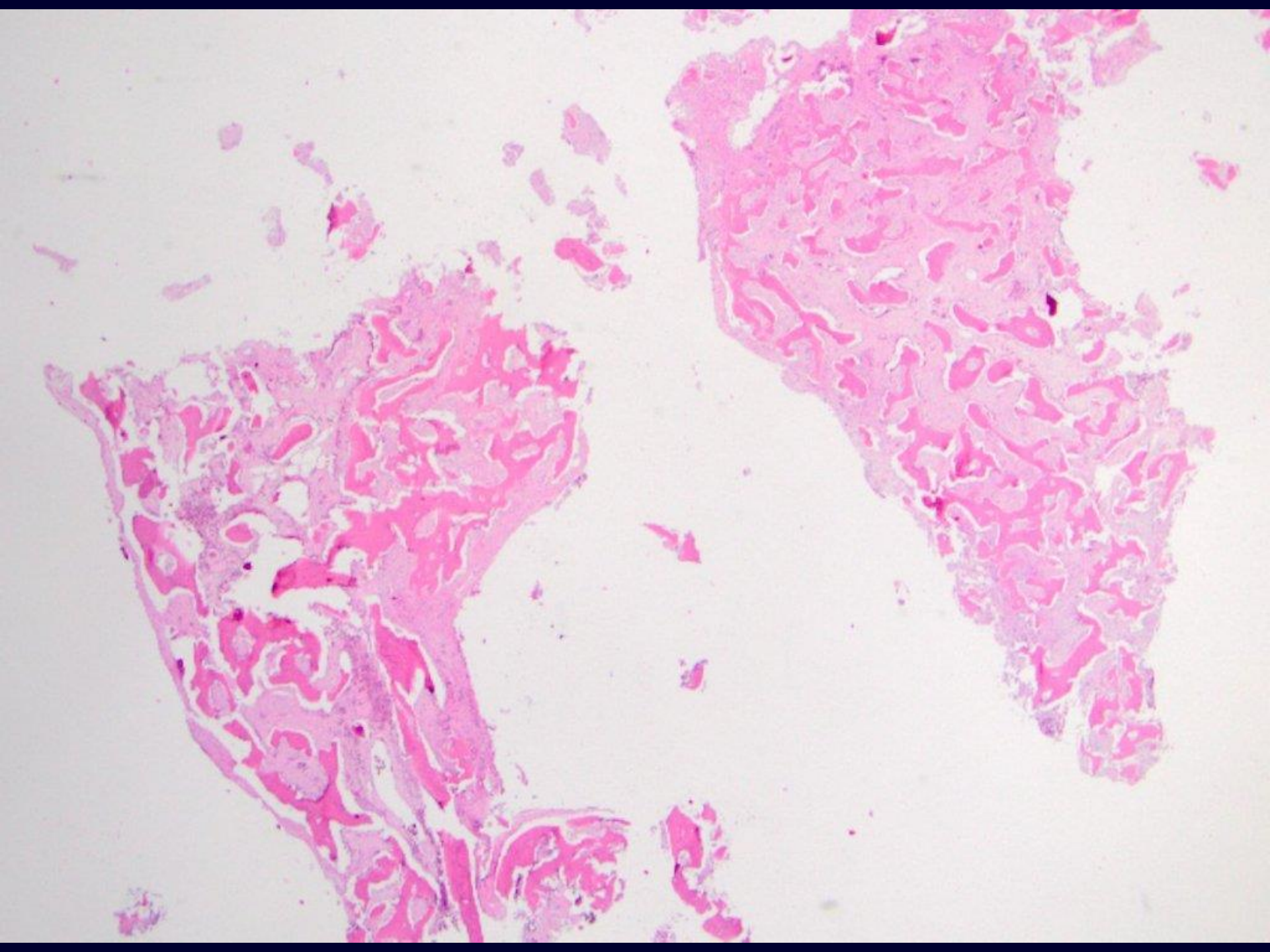
osteonecrosis (patient had exposure to Fosamax)

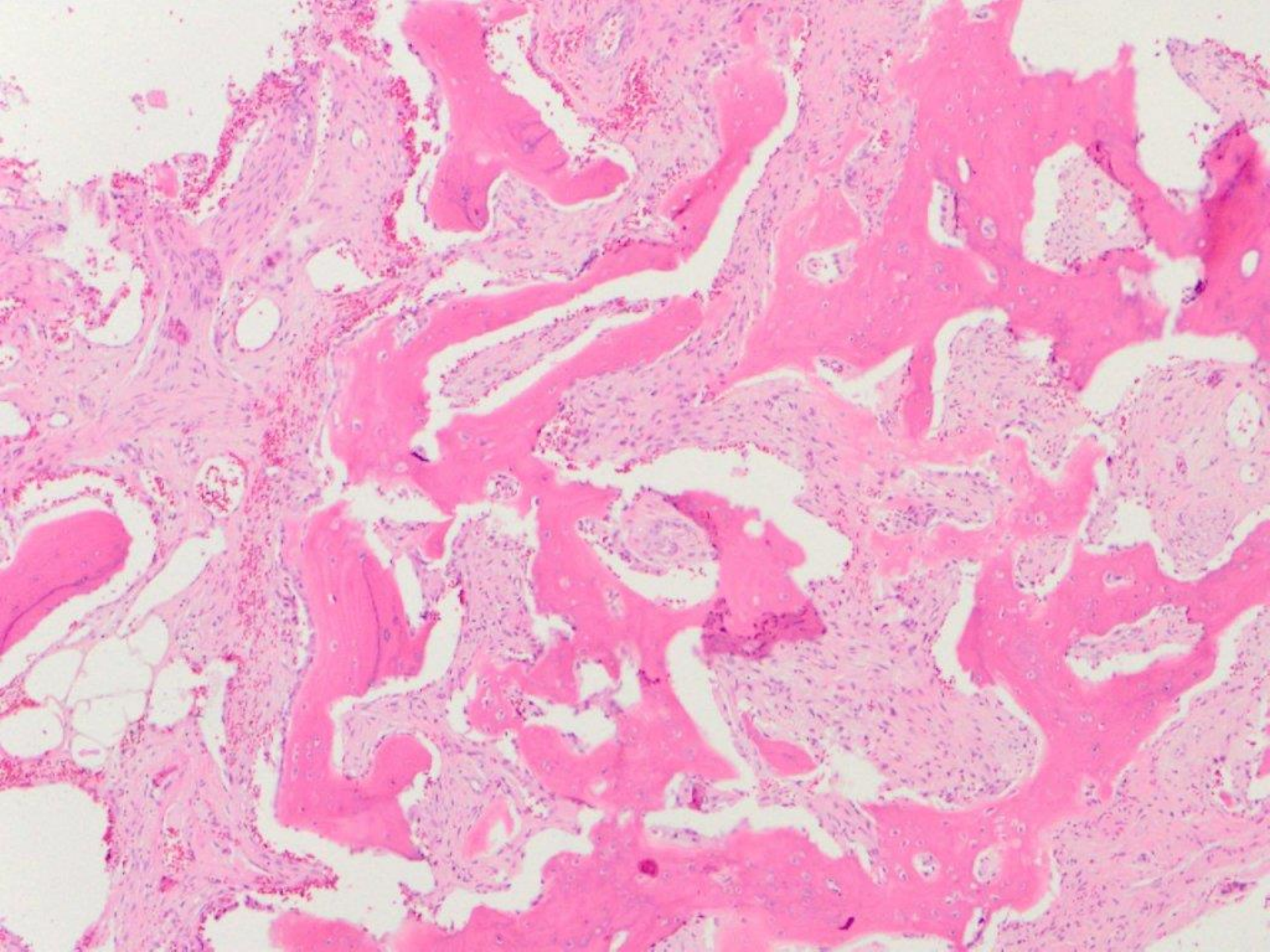


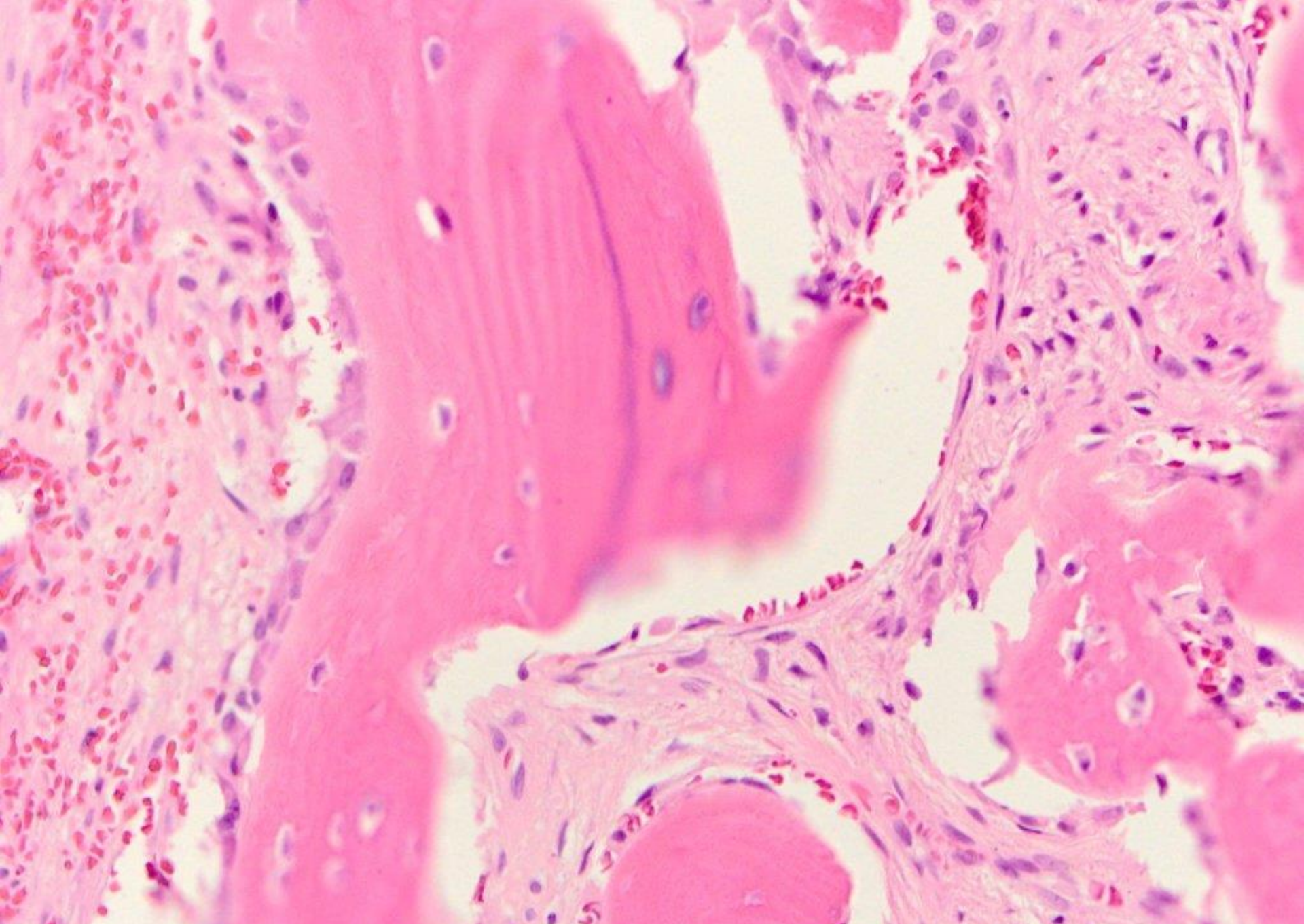




c/w fibrous dysplasia

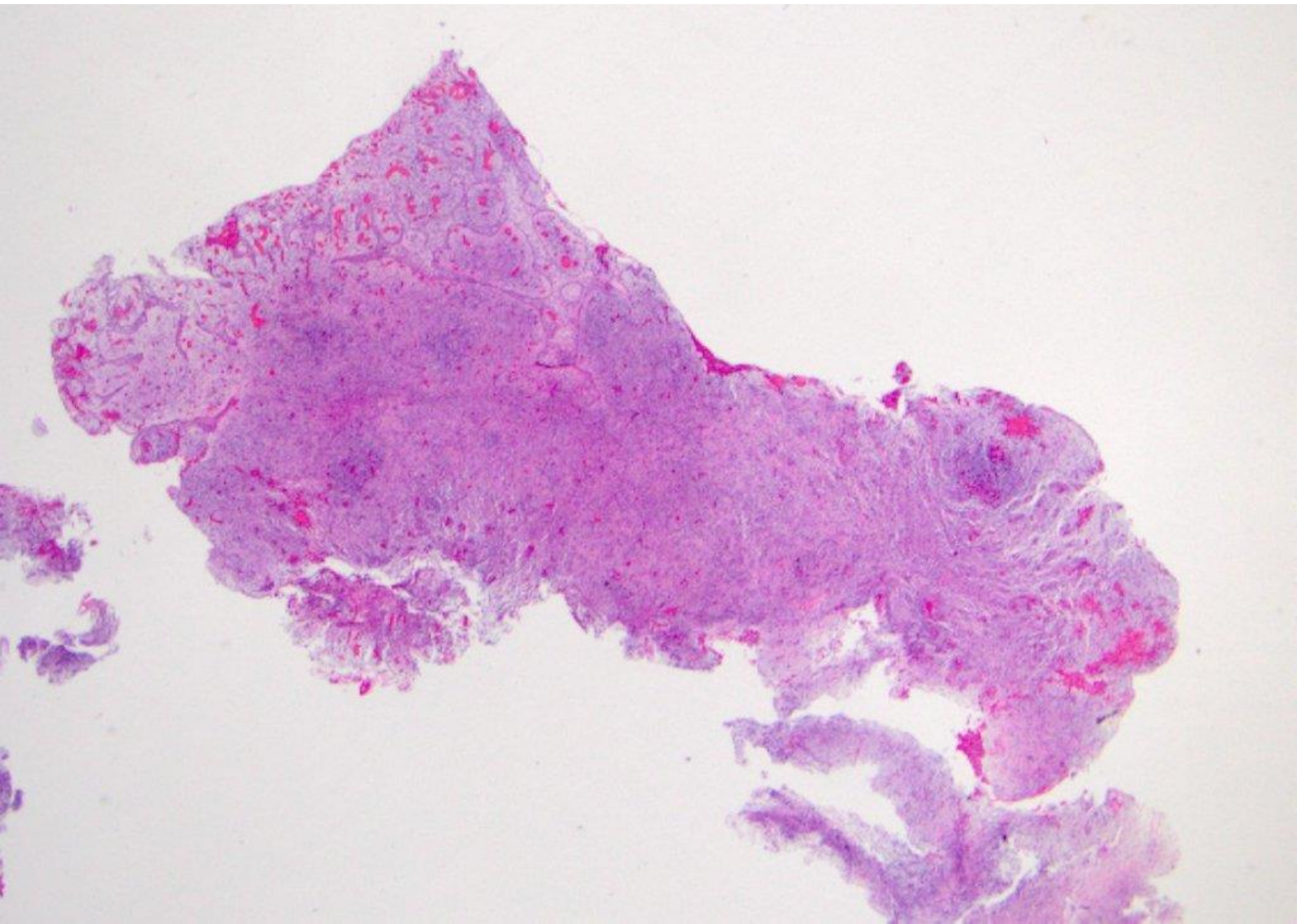


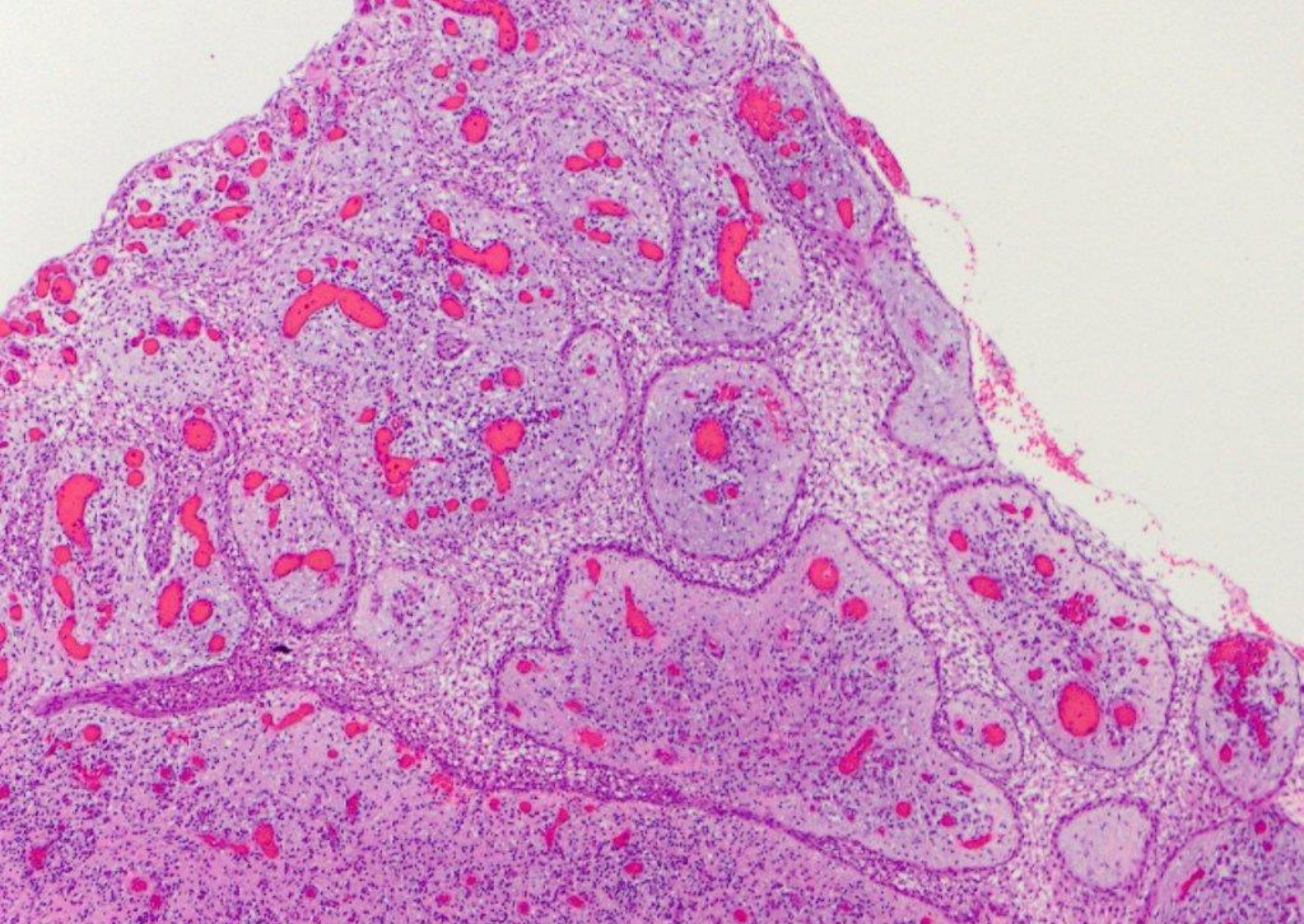




c/w fibrous dysplasia

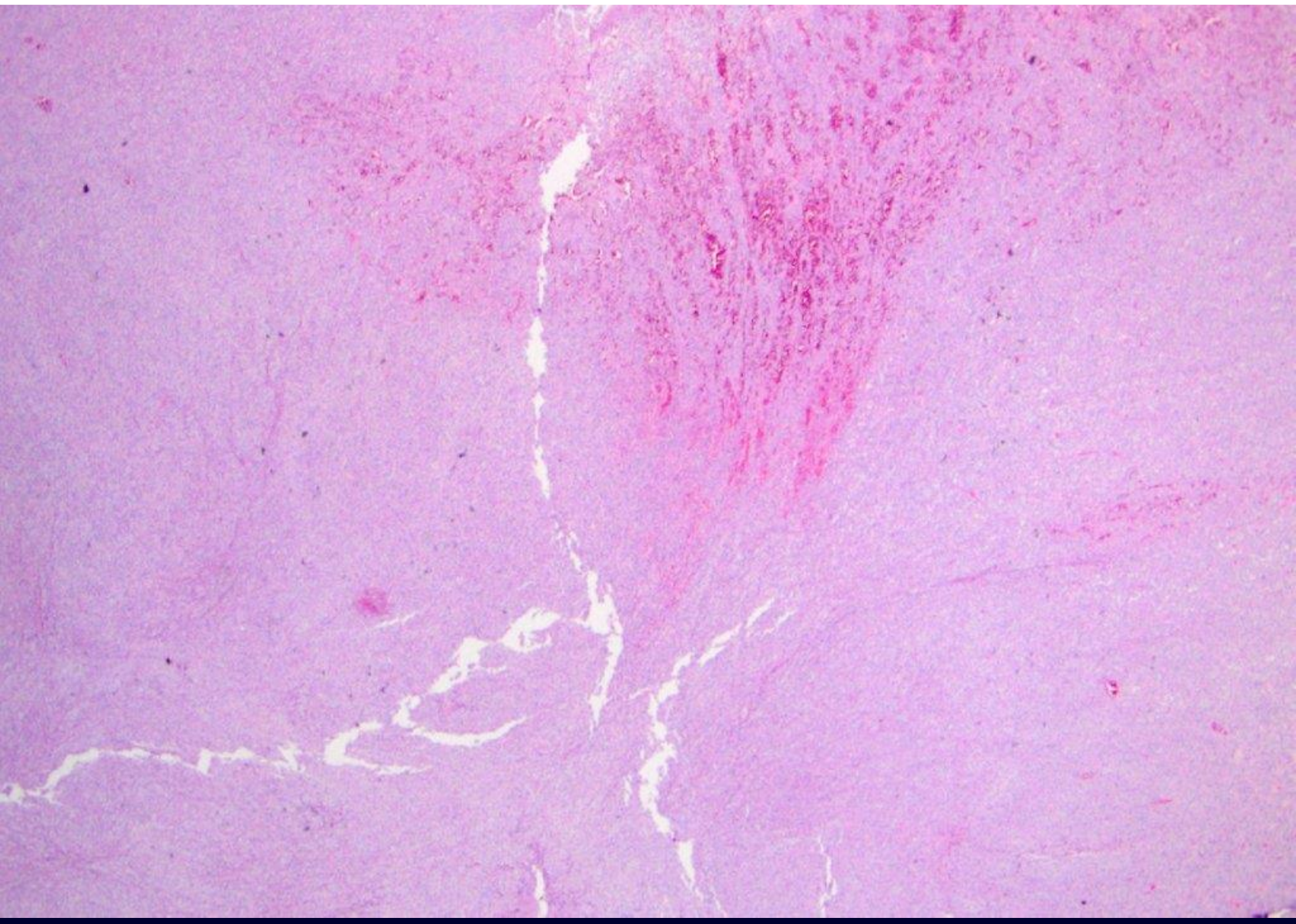
Radiographically, this is a second molar with a perifurcation/periradicular radiolucency

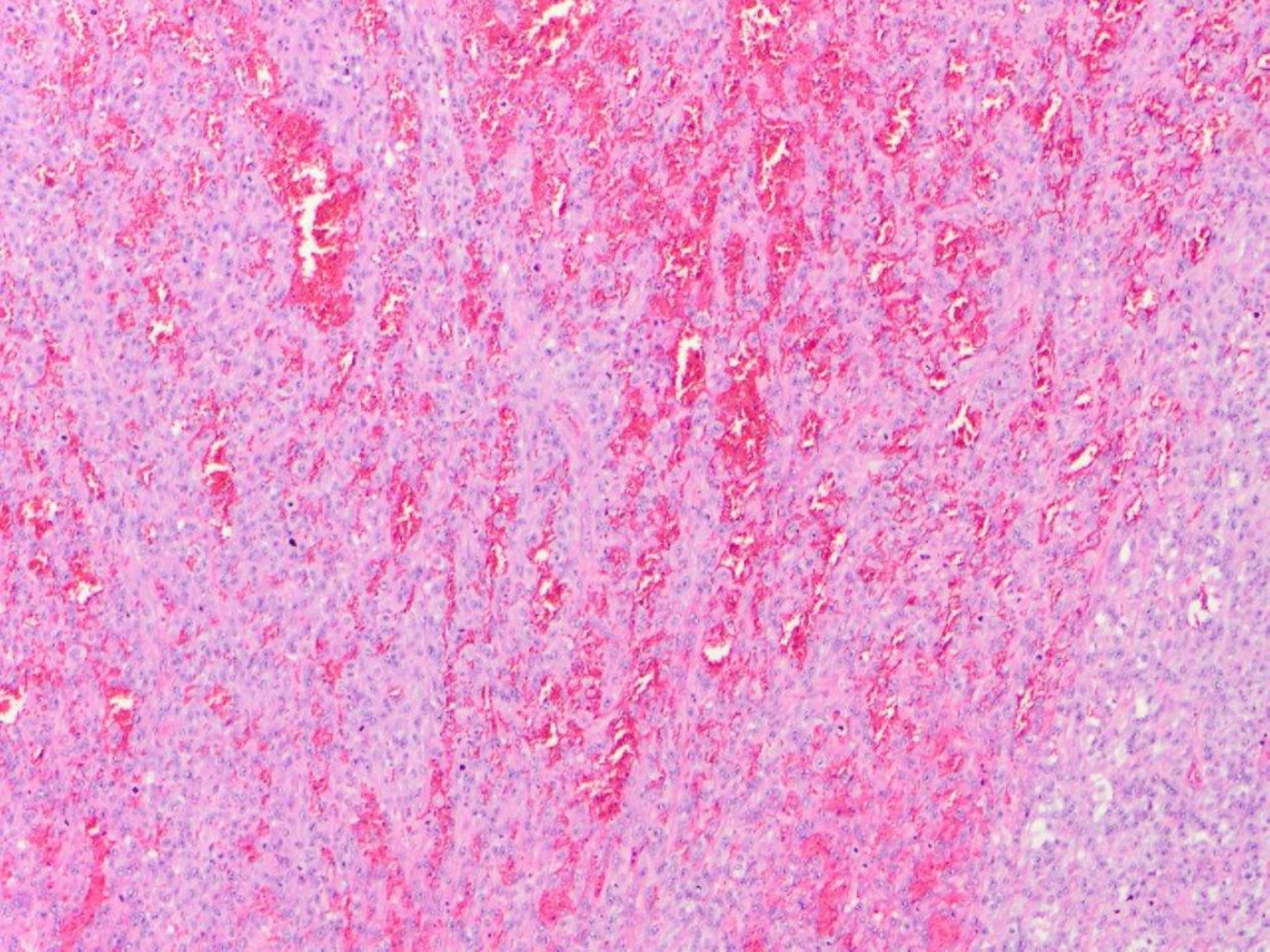


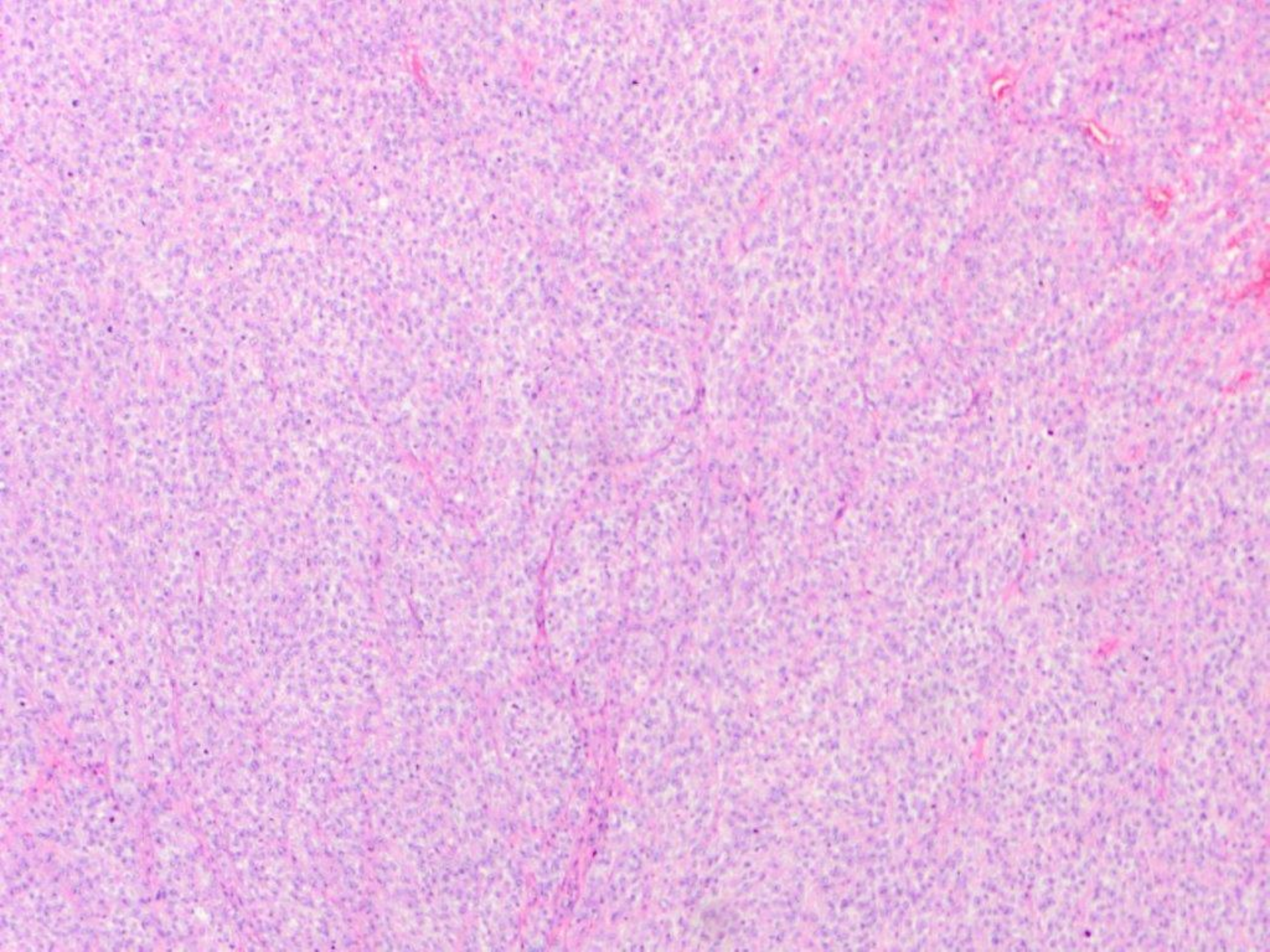


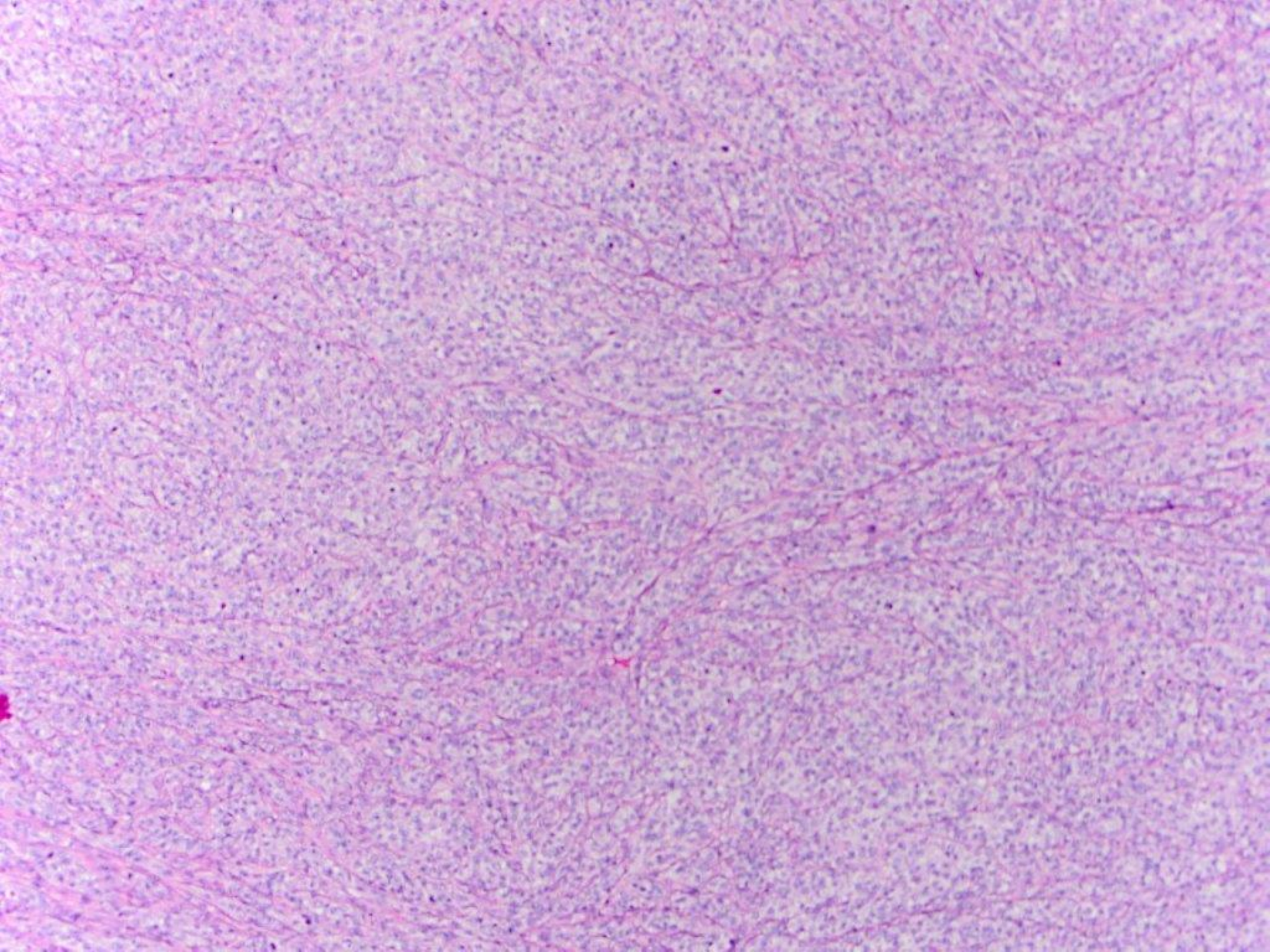
Inflammatory buccal cyst / buccal bifurcation cyst

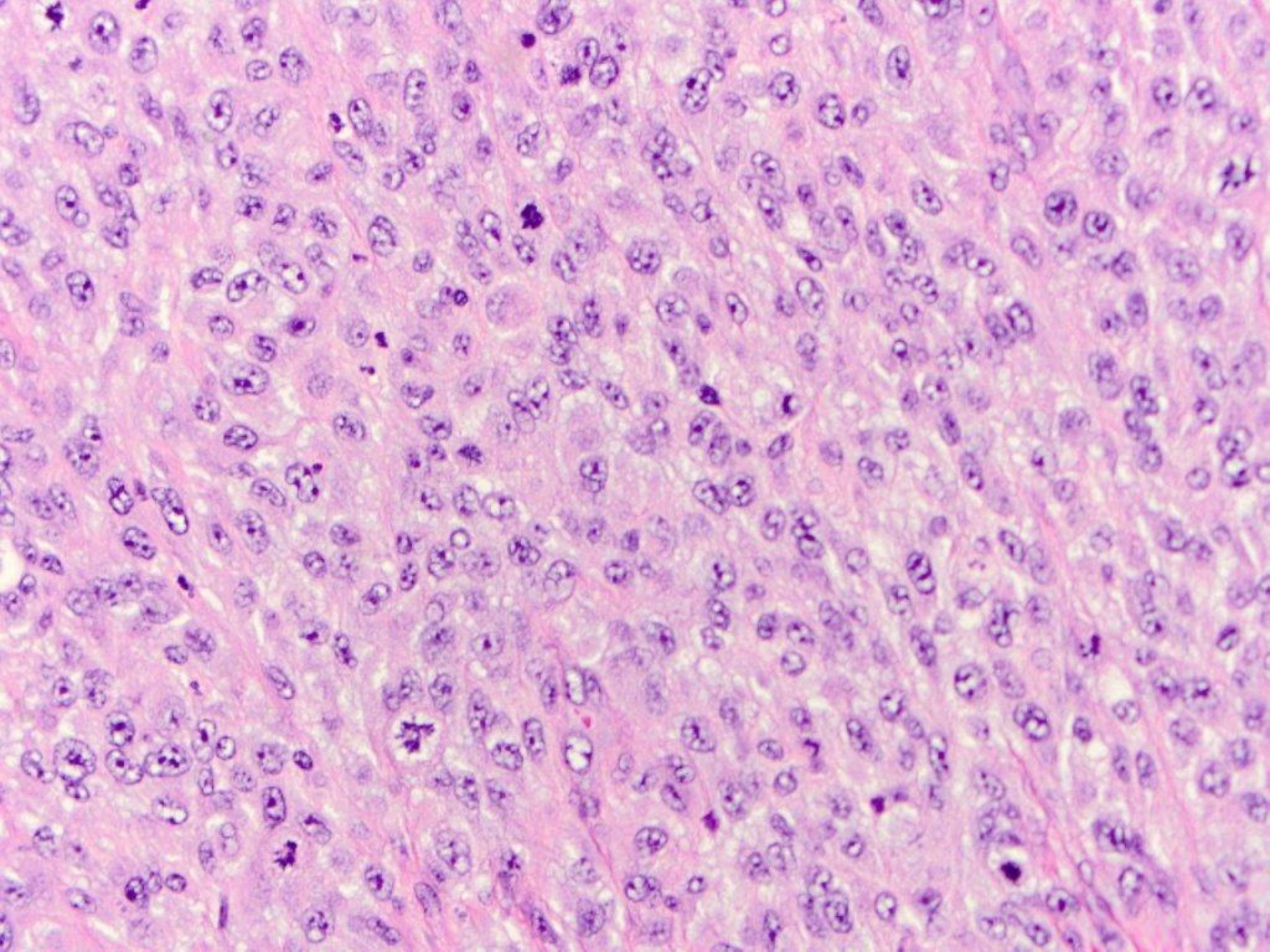
palate; history of cancer

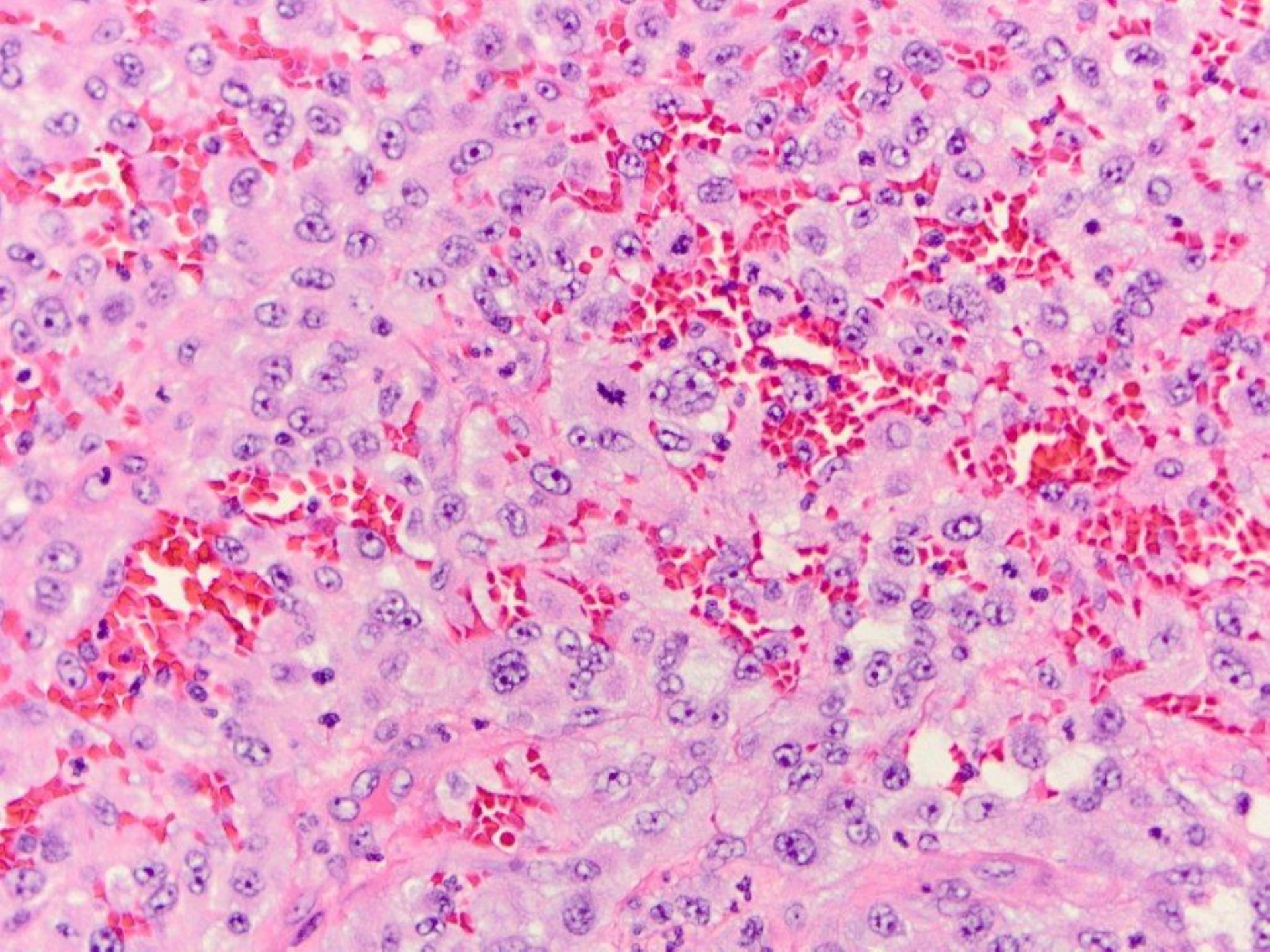


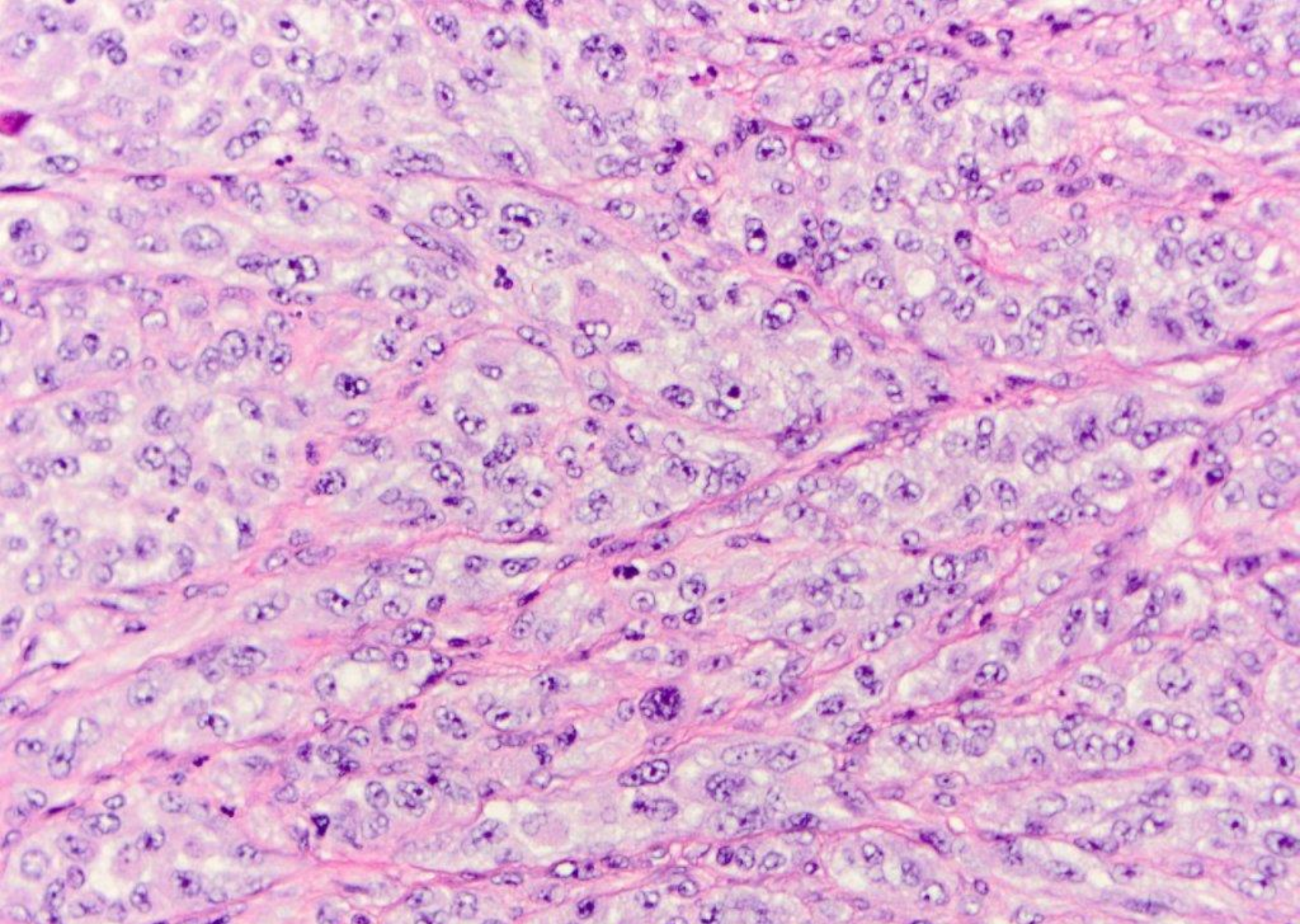




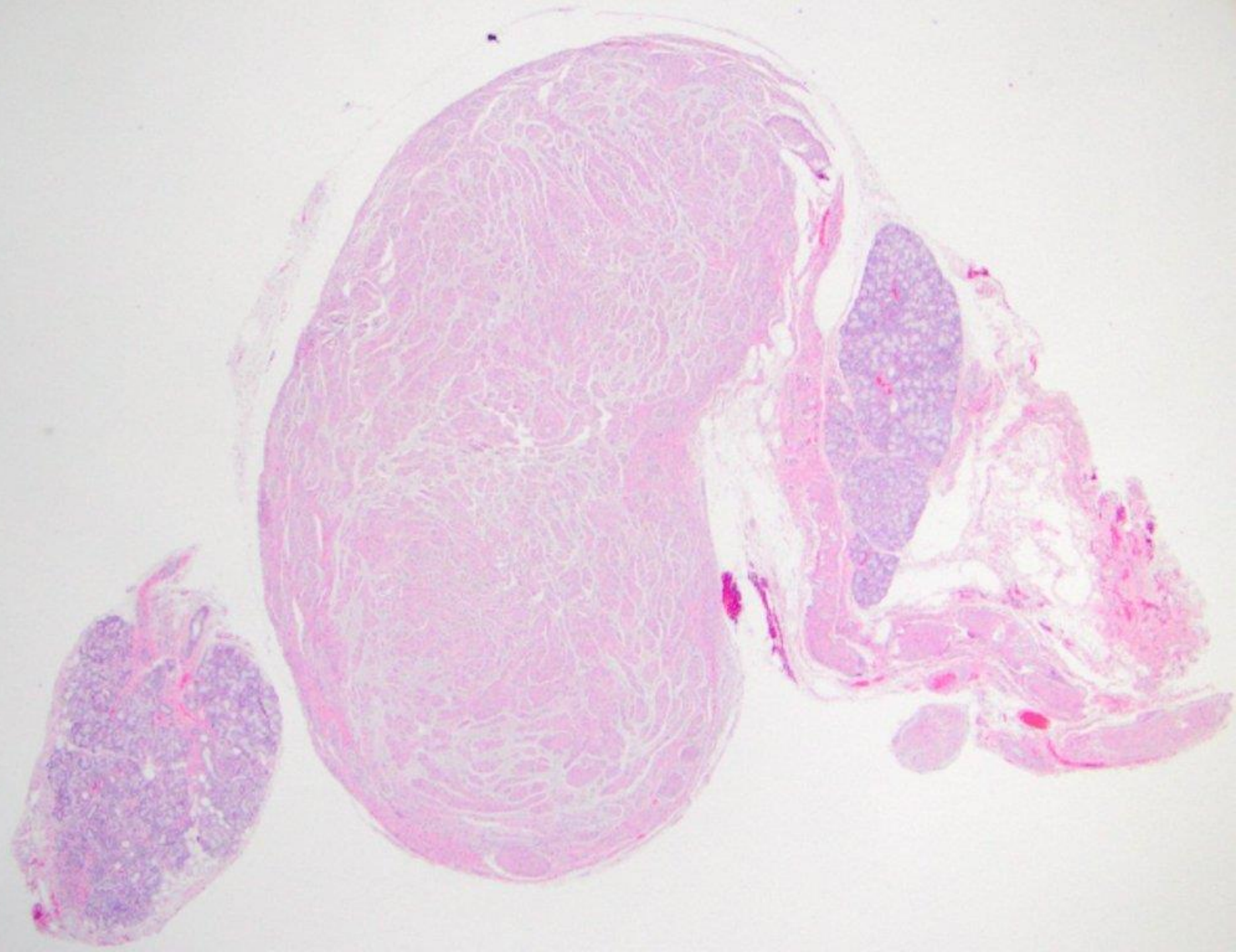


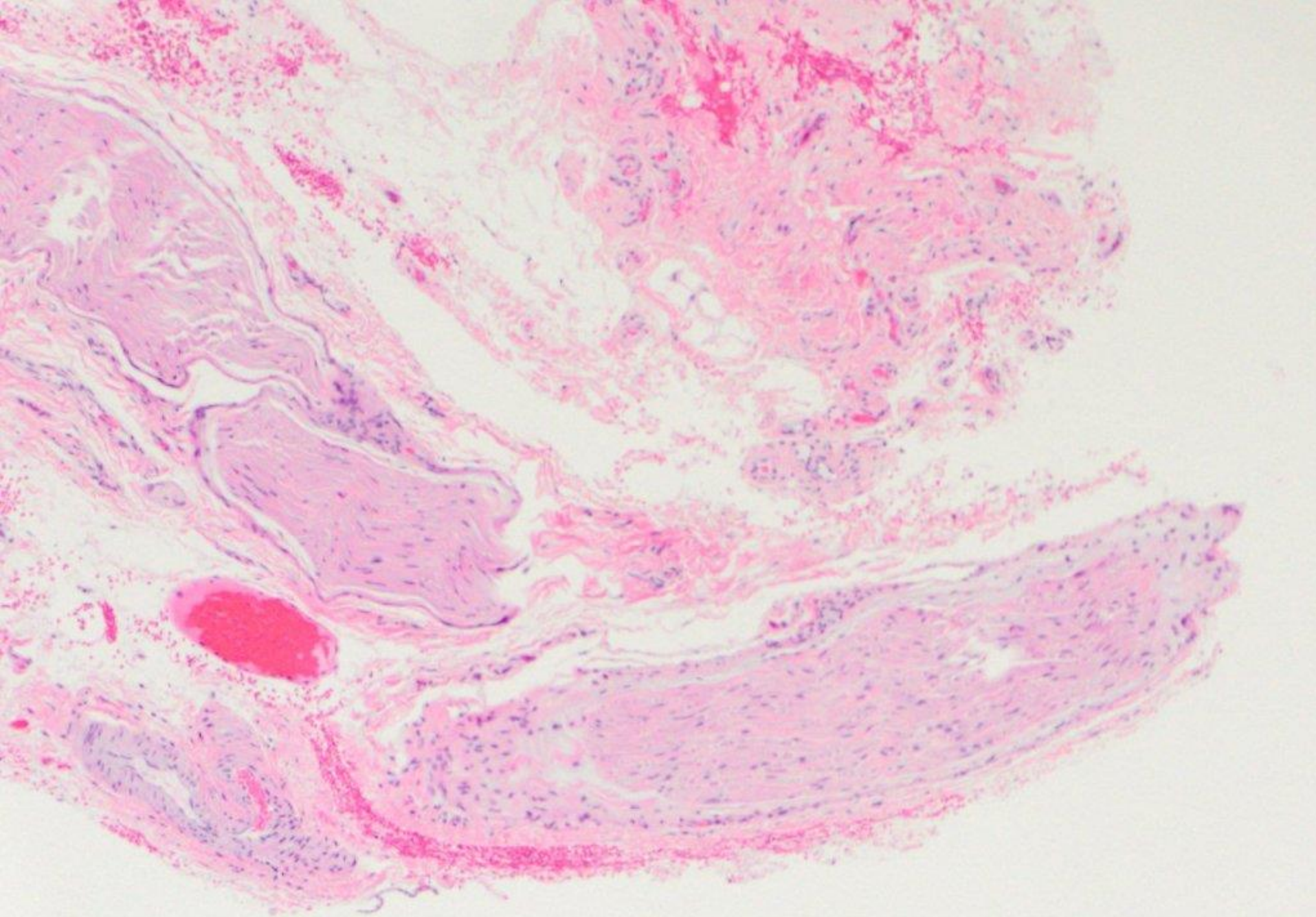


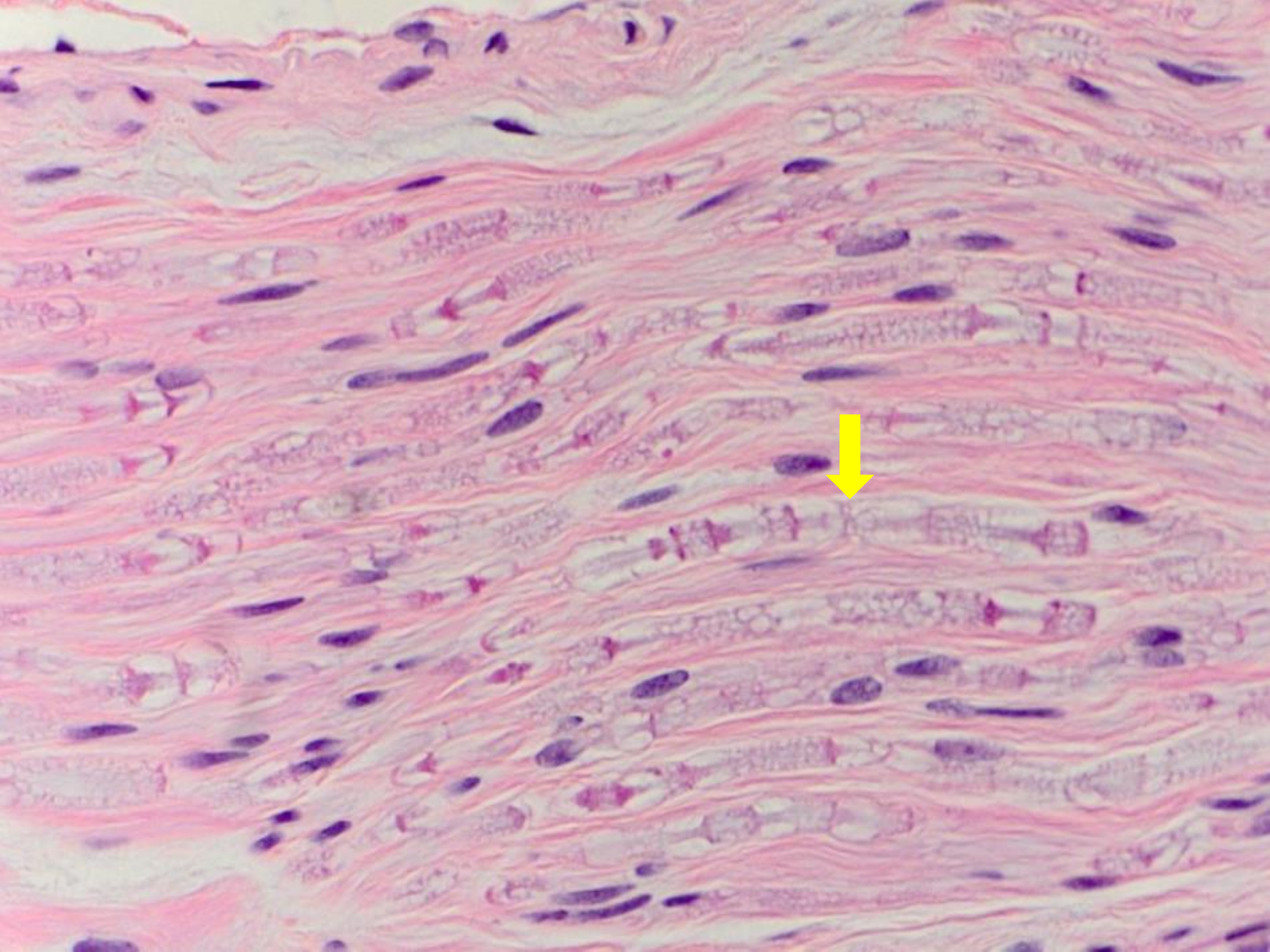


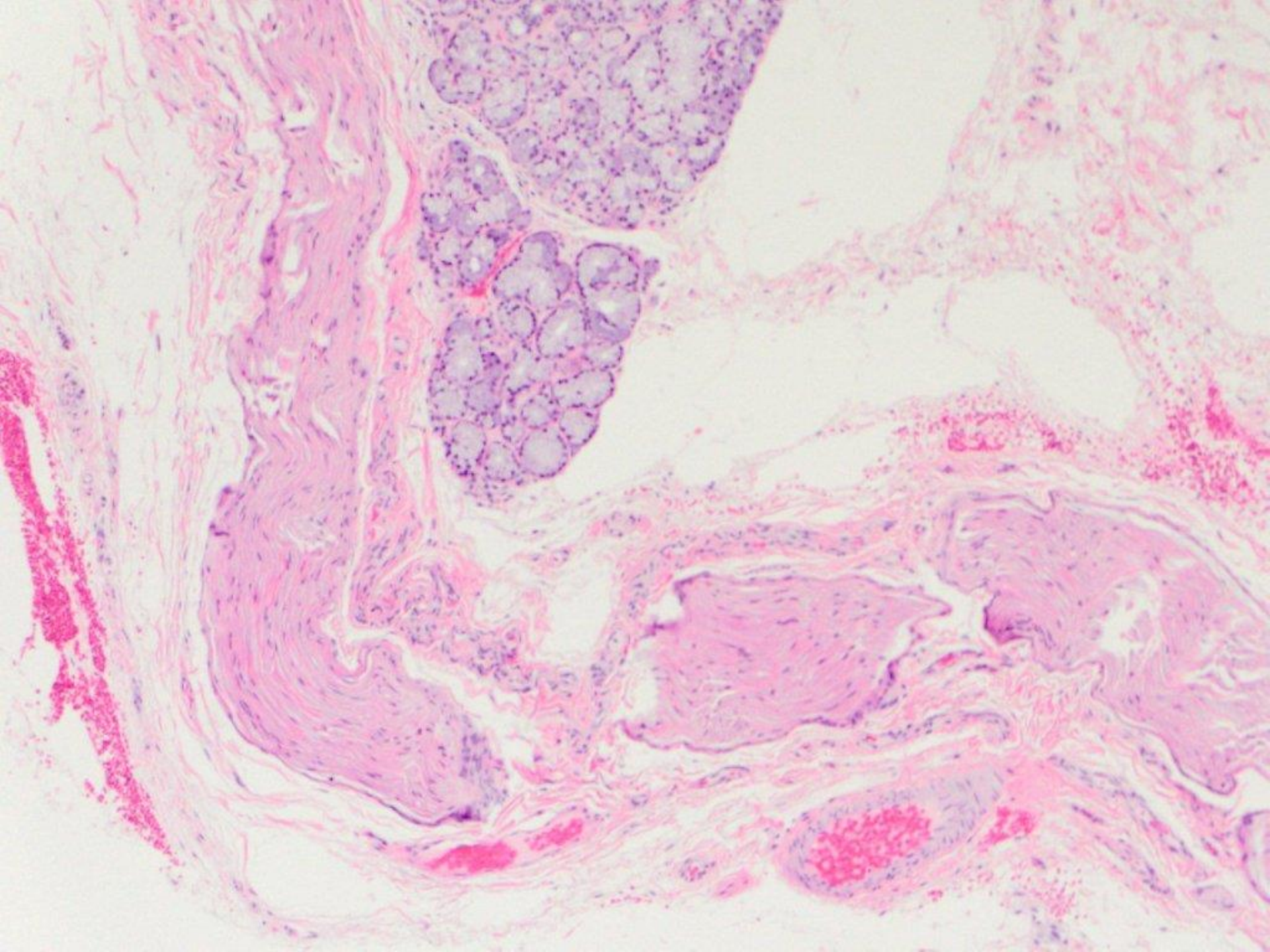


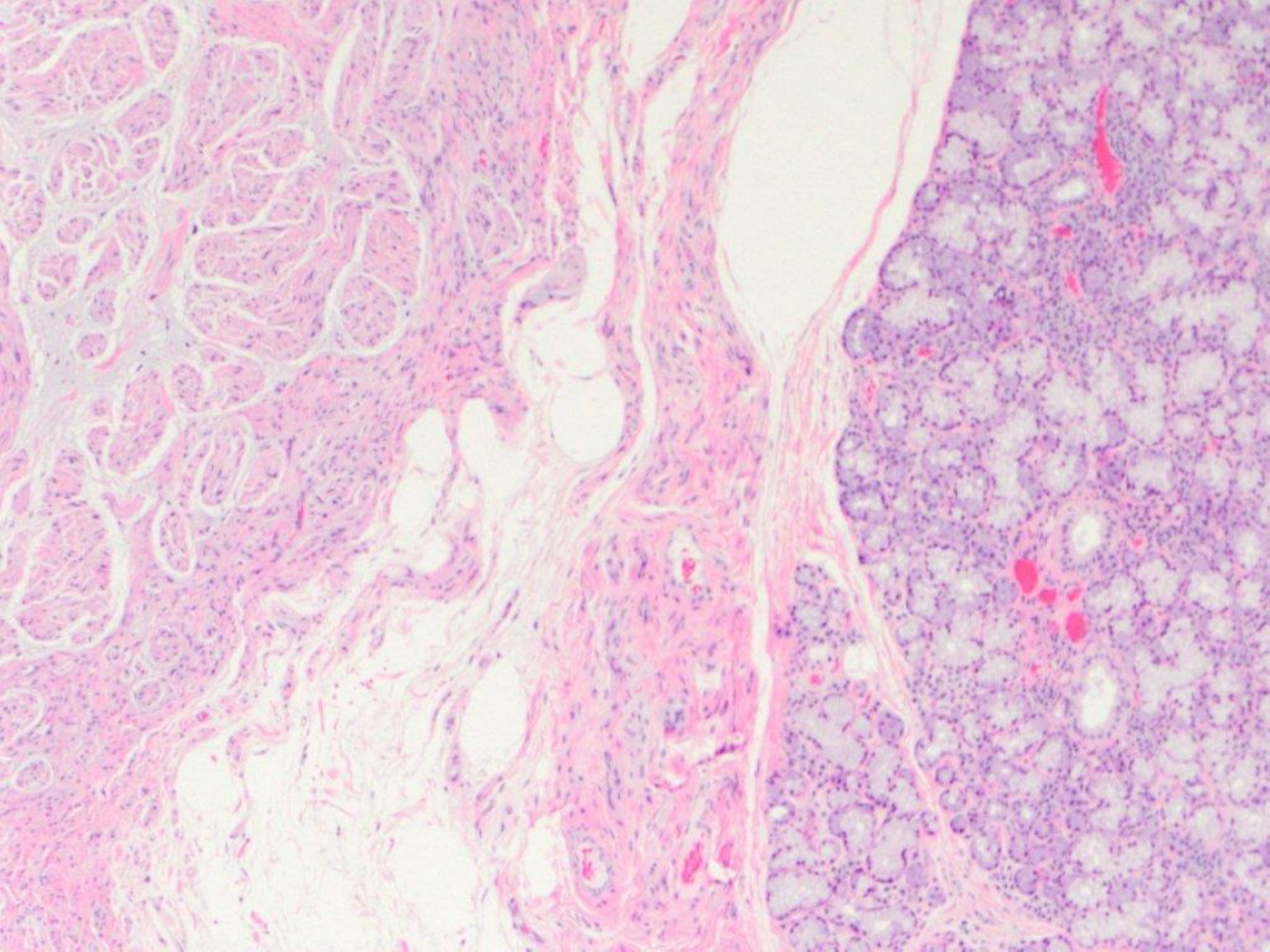
c/w renal cell carcinoma (patient had renal cell carcinoma with previously described metastases)

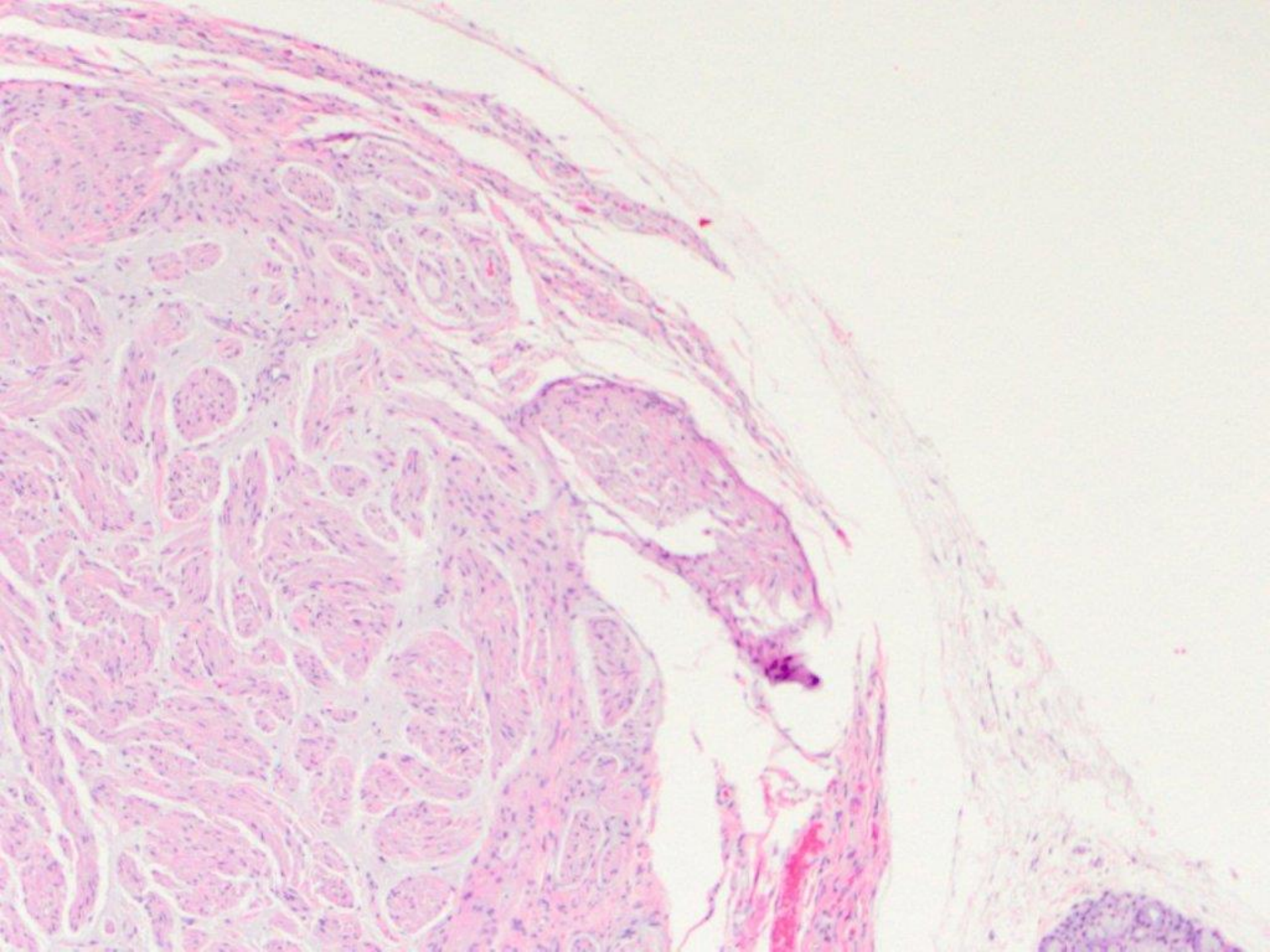


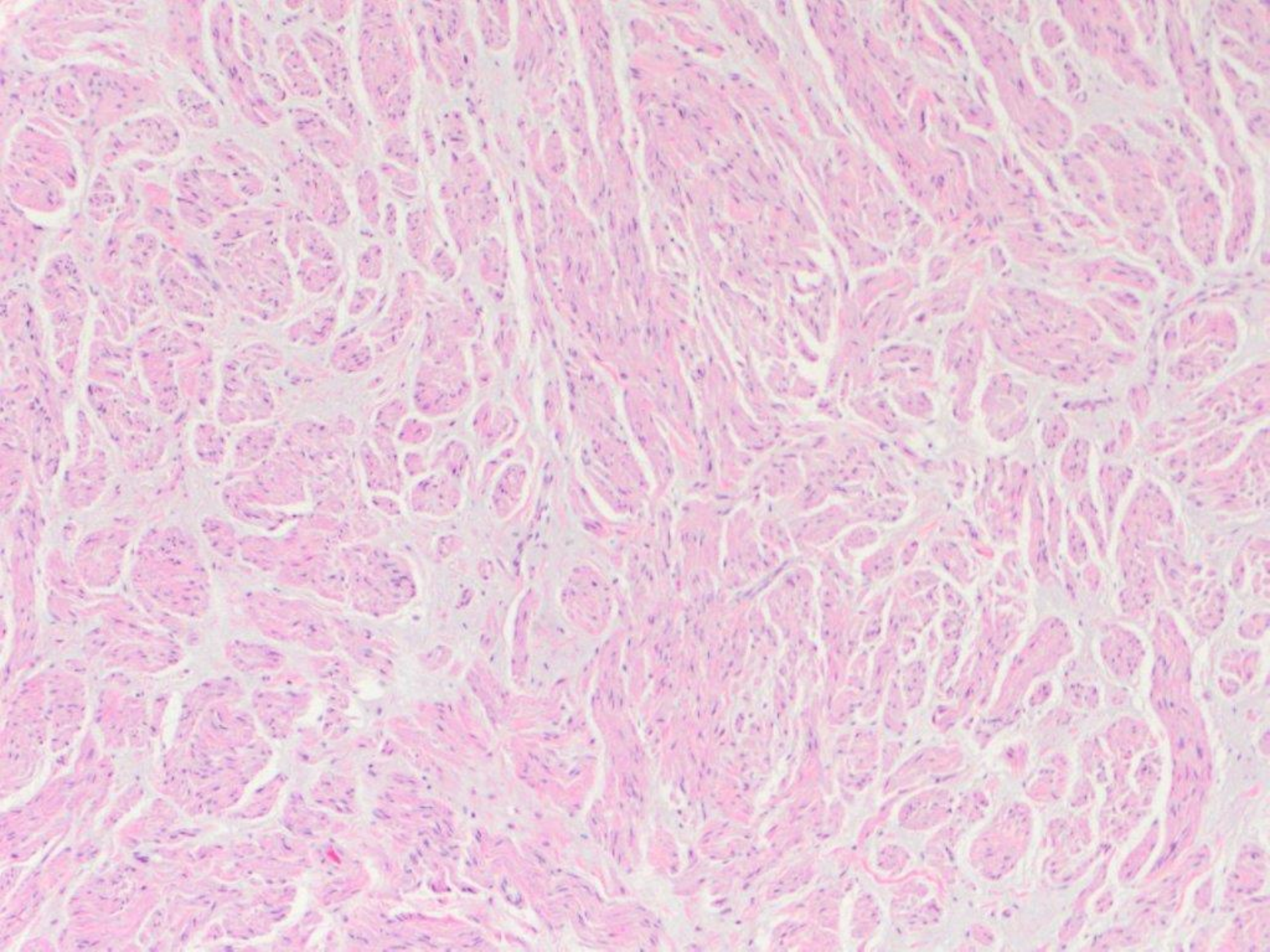


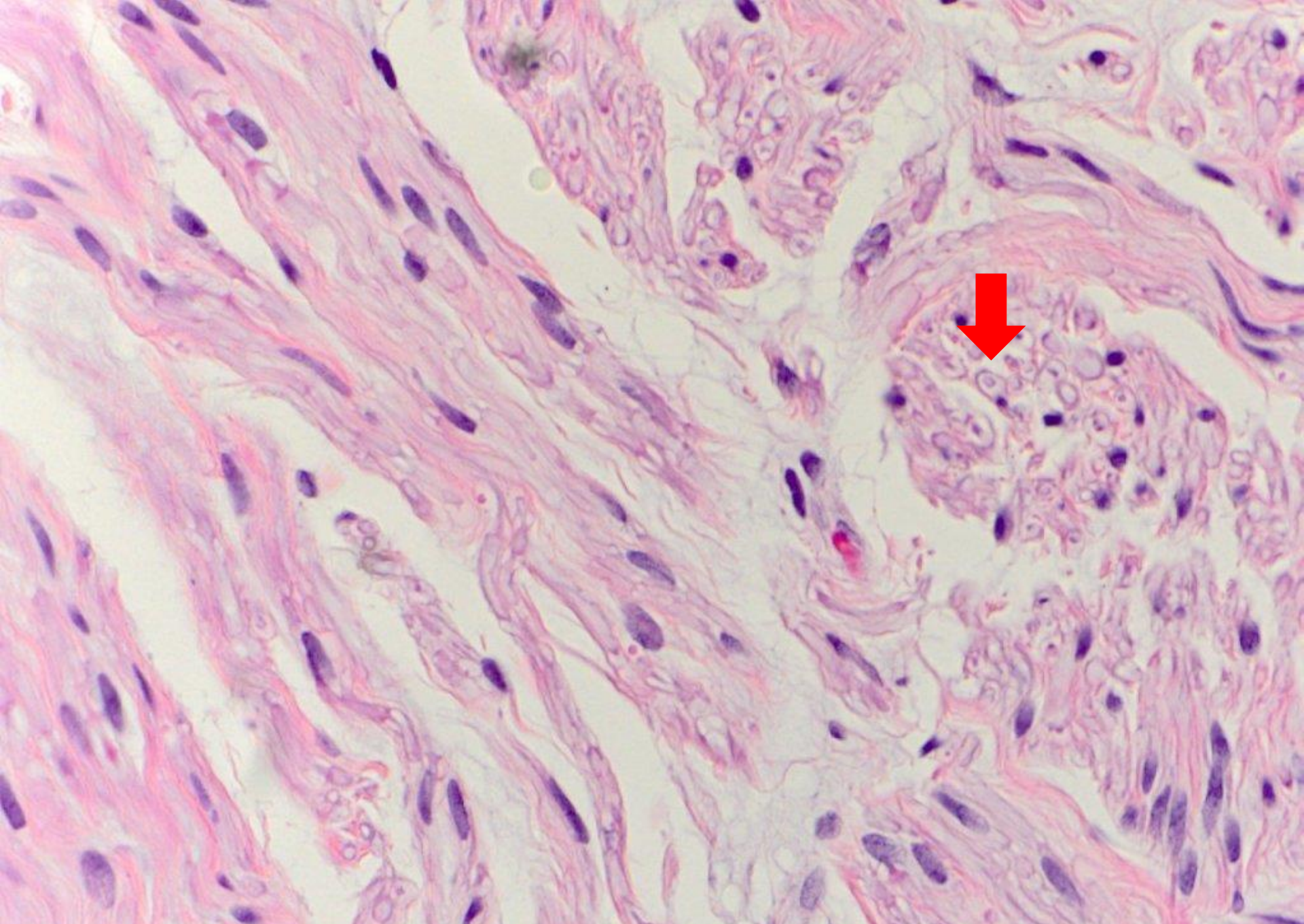












neuroma